



## SCEDOSPORIUM PROLIFICANS, AN UNUSUAL CAUSE OF FRONTAL ABSCESS

Beena<sup>†</sup> --- Sridhar Honappa<sup>2</sup> --- Naik Shalini Ashok<sup>3</sup>

<sup>1,2</sup>Department of Microbiology, M.S.Ramaiah Medical College and Teaching Hospital, Bangalore

<sup>3</sup>Department of Pathology, M.S. Ramaiah Medical College and Teaching Hospital, Bangalore

### ABSTRACT

*Scedosporium infections have become one of the most common cause of deep mold infections. It has also become a potentially dangerous causative agent of local and invasive infections in immunocompromised and occasionally in immunocompetent patients. It exhibits intrinsic resistance to many antifungals making the treatment difficult, thereby increasing the mortality. We present a case of an immunocompetent patient who came with a swelling on the left upper eyelid with a discharging sinus. A diagnosis of frontal lobe abscess was made and the mucopurulent discharge from the sinus was sent to the microbiology laboratory to know the etiology. The KOH wet mount of this discharge showed the presence of septate hyphal elements and the fungal culture yielded the growth of Scedosporium prolificans. The patient was treated with intravenous voriconazole to which he showed a favourable response.*

**Keywords:** Scedosporium, Immunocompetent, Swelling, Eyelid, Frontal lobe, Voriconazole.

### Contribution/ Originality

This study contributes in the existing literature with various clinical manifestations of Scedosporium like osteomyelitis, lung infection and infection in the transplant patients. This study is one of very few studies as scedosporium causing frontal lobe abscess...is rare. The paper's primary contribution is finding out the various causes of infections manifesting as a central venous system infection. This study documents that Scedosporium can enter the CNS through nasal septum and can be treated with voriconazole.

### 1. INTRODUCTION

Opportunistic fungal infections have become a recognised cause of infection in severely ill or immunocompromised patients. Though Aspergillus is a common cause of invasive infection, fungi-like Scedosporium have also become one of the important etiologic agents. Two important species, Scedosporium apiospermum and Scedosporium prolificans of this genus are major human pathogens. Perfect and Schell [1] they are saprophytic, dematiaceous mold, and both the species resemble each other morphologically. This fungus is ubiquitous, found in soil, sewage, polluted water. It was described as a human pathogen in 1984 as a causative agent of mycetoma. Kesson, et al. [2] scedosporium can cause asymptomatic, localised or disseminated infections depending on the immune status of the individual. Berenguer, et al. [3] here we report a case who presented with a swelling and discharging sinus on the left upper eyelid. A diagnosis of frontal lobe abscess was made. The aspirated pus was sent to microbiology laboratory for fungal culture, which grew Scedosporium prolificans.

Case- A 35-year-old male patient came with a history of painful swelling with discharge just above the left eye. Earlier to this, patient had come with a complaint of swelling over the left eyelid. A diagnosis of left orbital roof

chromoblastomycotic fungal granuloma was made and endoscopic excision of fungal granuloma from left orbit and anterior cranial fossa was done. He had completed a course of 1300 mg of liposomal amphotericin B infusion for 1 month.

After 6 months, the patient came again with a painful swelling at the operated site. On examination, a sinus was seen over the left upper eyelid with a mucopurulent discharge. The discharge was yellowish, mucopurulent. Ptosis was also seen. There was no H/O fever, nausea, vomiting or major illness like TB, hypertension or diabetes. All other vitals were stable. Clinical examination revealed Blood Pressure- 128/78 mmHg, Pulse rate- 78/min, Respiratory rate- 22/min, MRI of brain with contrast was done which showed frontal leptomeningeal enhancement, CT scan showed anterior cranial fossa extension.

Laboratory investigations were within normal limits (Table 1).The discharge and biopsy were sent to microbiology and pathology laboratory for fungal culture and histopathological examination(HPE) respectively. KOH wet mount of the aspirated pus showed the presence of septate hyphal elements. Fungal culture was done on Sabouraud's dextrose agar with and without antibiotic and incubated at 25° C. Rapidly growing, light gray to black, cottony growth which later became black with a black reverse was seen (Figure 1).Slide culture was done and the fungus was identified as *Scedosporium prolificans*. (Figure 2)

HPE showed an abscess with central necrosis, surrounded by inflammatory infiltrate. Periodic Acid Schiff stain and Gomori's methanamine silver stain showed multiple pigmented fungal colonies with septate hyphae embedded in cellular matrix which was suggestive of fungal infection. On the basis of the laboratory report, the patient was initially started on intravenous voriconazole and later orally for 14 days to which he responded without any recurrence. The sinus discharge from the left upper eyelid also resolved.

## 2. DISCUSSION

*Scedosporium* can cause life-threatening infections in susceptible patients and is considered as an emerging pathogen. De Hoog, et al. [4] *S.prolificans* infections in immunologically normal people remain localised, but in immunocompromised can cause disseminated infection. Monika, et al. [5]

This fungi causes various infections like soft tissue infection, septic arthritis, osteomyelitis, ophthalmic infection, pneumonia. Patients at risk are the immunocompromised, patients on immunosuppressive therapy and who are neutropenic [6]. In normal individuals, it causes localised infection due to penetrating trauma or aspiration of polluted water. In immunocompromised, it may cause severe pulmonary or disseminated infection. Patricia, et al. [7] *scedosporium apiospermum* and *Scedosporium prolificans* can also colonize abnormal airways caused by bronchiectasis, cystic fibrosis, chronic obstructive pulmonary disease or lung transplantation [6] *S.prolificans* is seen more in Haematopoietic stem cell transplant and Acute Myeloid Lymphoma patients than *S. apiospermum*. Host factors like neutropenia-associated macrophage dysfunction, environmental exposure in these conditions play a role in the patient being prone for *Scedosporium* infections. *S. prolificans* is more virulent and can cause life-threatening infections. Fungemia seen in this mold infection is also more common with *Scedosporium prolificans*. Infections by this species is difficult to treat as it is multi-drug resistant, leading to high mortality. Rodriguez-Tudela, et al. [8] successful treatment of *Scedosporium prolificans* can be obtained with a combination of voriconazole and terbinafine. Correction of neutropenia and surgery in localised infection helps.

The ability of this organism to grow on cycloheximide medium is variable and this can be used to differentiate *S. apiospermum* from *S. prolificans* which is unable to grow in the presence of cycloheximide. De Hoog, et al. [4] the clinical features and histopathology of *Scedosporium* are similar to *aspergillus*, *fusarium* and other common hyphomycetes, therefore diagnosis of *scedosporium* infection is difficult. Sporulation by slide culture would be required for the correct diagnosis.

Our patient was immunologically competent with no underlying predisposing risk factors. There was no other systemic fungal infection. Despite this, the patient developed locally invasive frontal lobe abscess. Probably here, the portal of entry could be the sinus or nasal septum with invasion of the bony margin and then extending into the frontal lobe leading to purulent abscess. This probable mode of infection was also explained by [Gluckman, et al. \[9\]](#) since the fungus is ubiquitously seen in soil, sewage and polluted water, other portals of entry could be through trauma or aspiration of polluted water. A similar case like ours, with the patient having sinusitis and later complicated by development of left orbital cellulitis was reported. [Andrew, et al. \[10\]](#) other studies like *Scedosporium* causing disseminated infection involving the lungs, osteomyelitis due to penetrating injury have also been reported.

### 3. CONCLUSION

*Scedosporium species* are pathogenic fungi of increasing clinical importance, particularly in persons with underlying diseases. They demonstrate distinct clinical features depending on the immune function of the host and the type of species isolated. Their inherent resistance to many antifungals makes the infection with this fungi more challenging to manage. An early diagnosis with a suitable antifungal would help in containing this infection.

### 4. RECOMANDATIONS

Over the recent years, fungal infections have increasingly become common owing to various predisposing factors. Hence, a fungal etiology should also be considered as one of the differential diagnosis in order to start the treatment early and reduce the fatal outcome.

### REFERENCES

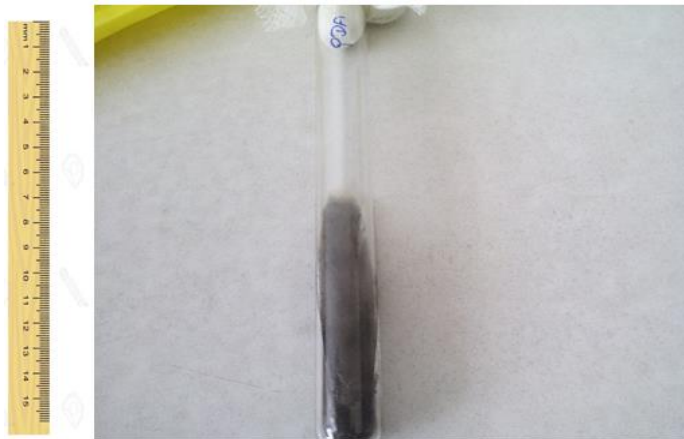- [1] J. Perfect and W. Schell, "The new fungal opportunists are coming," *Clin. Infect Dis.*, vol. 22, pp. 112-118, 1996.
- [2] A. Kesson, M. Bellemore, T. O'Mara, D. Ellis, and T. Sorrell, "Scedosporium prolificans osteomyelitis in an immunocompetent child treated with a novel agent, hexadecylphosphocholine (Miltefosine) in combination with terbinafine and voriconazole: A case report," *Clin. Infect Dis.*, vol. 48, pp. 1257-1261, 2009.
- [3] J. Berenguer, J. Rodriguez-Tudela, C. Richard, and M. Alvarez, "Deep infections caused by scedosporium prolificans, a report on 16 cases in Spain and review of the literature. Scedosporium prolificans Spanish study group," *Medicine*, vol. 76, pp. 256-65, 1997.
- [4] G. S. De Hoog, F. Marvin Sikkema, and G. Lahpoo, "Ecology and physiology of the emerging opportunistic fungi pseudoallescheria boydii and scedosporium prolificans," *Mycoses*, vol. 37, pp. 71-78, 1994.
- [5] M. Monika, K. Ravinder, and A. Shweta, "A case of scedosporium prolificans osteomyelitis in an immunocompetent child misdiagnosed as tubercular osteomyelitis," *Indian J. Dermatol.*, vol. 58, pp. 80-81, 2013.
- [6] C. Louise, S. Denis, T. Karin, and S. Monica, "Infection with Scedosporium apiospermum and S. Prolificans, Australia," *Emerg. Infect Dis.*, vol. 13, pp. 1170- 1177, 2007.
- [7] M. Patricia, M. Marin, P. Tornero, R. P. Martin, M. Rodriguez, and E. Bouza, "Successful outcome of scedosporium apiospermum disseminated infection treated with voriconazole in a patient receiving corticosteroid therapy," *Clin. Infect Dis.*, vol. 31, pp. 1499-1501, 2000.
- [8] J. Rodriguez-Tudela, J. Berenguer, J. Guarro, A. Kantarcioglu, R. Horre, and G. De Hoog, "Epidemiology and outcome of scedosporium prolificans infection, a review of 162 cases," *Med. Mycol.*, vol. 47, pp. 359-370, 2009.
- [9] S. Gluckman, K. Ries, and E. Abrutynm, "Allescheria (Petriellidium) boydii sinusitis in a compromised host," *J. Clin. Microbiol.*, vol. 5, pp. 481-484, 1977.

- [10] F. H. Andrew, R. C. Jose, A. B. Michelle, and C. N. Aran, "Combination antifungal therapy in the treatment of scedosporium apiospermum central nervous system infections," Case Reports in Infectious Diseases, 2013.

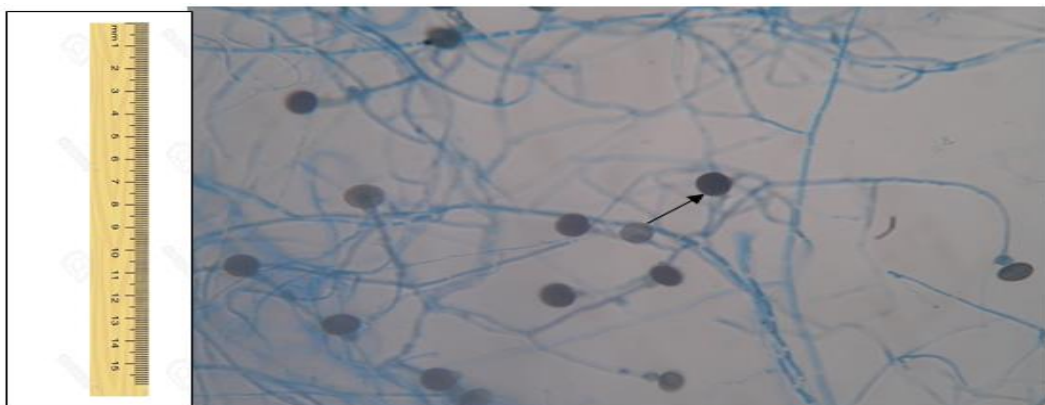
**Table-1.** Laboratory Investigations

Haemoglobin	13.0 gm/dl
Total wbc count	4660 cells/cumm
Neutrophils	49%
Lymphocytes	43%
Eosinophils	3%
Monocytes	5%
Basophils	0%
Platelet count	2.05 lakhs
ESR	14mm/hr

## LEGENDS



**Figure-1.** Showing growth of Scedosporium on Sabouraud's dextrose agar.



**Figure-2.** Showing Lactophenol cotton blue mount of slide culture of Scedosporium proliferans. (↑) indicates lollipop appearance of spores.

*Views and opinions expressed in this article are the views and opinions of the author(s), Genes Review shall not be responsible or answerable for any loss, damage or liability etc. caused in relation to/arising out of the use of the content.*