



ABOUT THE PATHOGENESIS OF MYASTHENIA GRAVIS ASSOCIATED WITH THYMIC ENLARGEMENT

Mona Mlika^{1†} --- Wided Ajouli² --- Adel Marghli³ --- Faouzi Mezni⁴

^{1,2,3}Department of Pathology, Abderrahman Mami Hospital, Ariana, Tunisia

⁴Department of Thoracic & Cardiovascular Surgery, Abderrahman Mami Hospital, Ariana, Tunisia

ABSTRACT

Introduction: A causal relationship between the thymus gland and myasthenia gravis (MG) has been assumed for decades. However, this relationship is still a matter of conjecture and speculations and awaits definitive proof. Recently, myoid cells have been considered as effectors in the pathogenesis of MG as well as thymic enlargement (thymolipoma, true thymic hyperplasia). Material and methods: we report a retrospective study about 6 cases of thymic enlargement with 4 cases of true thymic hyperplasia (TTH) and 2 cases of thymolipoma (TL). Aim: Our objective is to discuss the role of myoid cells in the pathogenesis of MG associated with thymic enlargement. Results: The majority of our patients were men with a sex ratio of 4/2. Only 2 patients had a past medical history consistent for MG. Myoid cells were found in all cases. Conclusion: Through our small study, the implication of myoid cells in the pathogenesis of the association MG-TL or TTH remains unproved.

Keywords: Pathogenesis, Masthenia gravis, Thymic enlargement, Thymic hyperplasia, Pathology, Surgery.

Received: 11 November 2014/ **Revised:** 6 December 2014/ **Accepted:** 14 January 2015/ **Published:** 24 March 2015

Contribution/ Originality

This study contributes in the existing literature by enriching our knowledge about the pathogenesis of myasthenia gravis.

1. INTRODUCTION

A causal relationship between the thymus gland and myasthenia gravis (MG) has been assumed for decades. However, this relationship is still a matter of conjecture and speculation and awaits definitive proof. It has been more than three decades since modern surgery has taken a role in the treatment of myasthenic patients [1]. During the same period we have achieved new

[†] Corresponding author

© 2015 Conscientia Beam. All Rights Reserved.

knowledge of the anatomical, physiological and pharmacological abnormalities of the thymus in MG. The immunological aspects of the thymus gland have been the targets of recent interest and the role of the thymus in myasthenic patients has slipped into the background.

Recently, myoid cells have been considered as effectors in the pathogenesis of MG as well as thymic enlargement (thymolipoma, true thymic hyperplasia).

2. MATERIAL AND METHODS

Six cases of thymic enlargement were diagnosed at the department of Pathology of our hospital. Clinical records, histological reports and microscopic slides were available in all cases and were retrospectively reviewed. Our study contained 2 groups: four patients without medical history of myasthenia gravis (MG) and two patients, which were myasthenic. All patients underwent a clinical examination, standard chest radiographs and computed tomography scans (CT). Diagnosis of thymic enlargement (thymolipoma (TL) or true thymic hyperplasia (TTH)) was made on surgical biopsies in 2 cases and on thymectomy in 4 cases. All samples were fixed in formalin, embedded in paraffin and stained with hematoxylin and eosin. An additional immunohistochemical study was performed, in all cases, using the following anti - bodies: anti-desmin and anti- smooth muscle actin (SMA). These antibodies were used in order to reveal myoid cells.

3. RESULTS

The clinical characteristics are summarized in table 1

3.1. Clinical Records

Our study contained 4 men and 2 women (sex ratio= 2) ranging in age from 14 to 48 years (mean age = 24.66 years). The 2 patients with MG underwent a thymectomy because of resistance to the medical treatment. Two patients were treated with chemotherapy for a Burkitt lymphoma in one case and ovarian immature teratoma in the other. The fifth patient had a history of Cushing syndrome and the sixth one was operated for cystic pleurisy. Chest -x-ray revealed a mediastinal enlargement in 4 cases and was normal in the others. CT-scan demonstrated an anterior mediastinal mass in 4 cases and was normal in 2 cases.

3.2. Histological Findings

There were 4 cases of TTH and 2 cases of TL. Concerning the 2 patients with MG, one case was associated with a TL and the other with a TTH.

TTH showed numerous lobules with well-defined cortical and medullary areas thus resembling the normal thymus (Figure 1a). TL was composed of abundant mature fatty tissue with scattered thymic islands including Hassall's corpuscles (Figure 1b).

Immunohistochemical staining revealed a positivity of spindle medullary cells for desmin and smooth muscle actin in all cases indicating the presence of myoid cells in all cases (Figure 2).

4. DISCUSSION

MG is a relatively uncommon disease of the neuromuscular junction whose effectors are autoantibodies against the nicotinic acetylcholine receptor (AChR) at the postsynaptic membrane of the neuromuscular junction. Thymic abnormalities are found in patients with MG. About 70% of the patients with MG have thymic follicular hyperplasia, 15% have thymomas, and 15% have a histologically normal thymus for their age [2]. Thymic enlargement (true thymic hyperplasia or thymolipoma) has been associated with the early onset of the disease. Moreover, thymectomy improves the clinical course of MG. The thymus is implicated in initiating or perpetuating the disease process. Many theories were advanced to explain the pathogenesis of this autoimmune entity [3-9]. According to one theory, this disease is a B-cell-mediated disease. It is thought that the thymic germinal center environment, observed in lymphoid thymic hyperplasia, is providing signals that promote auto-reactive B-cell survival, activation and maturation. These cells will block the AChR [7]. Other theories implicated the role of the T-cell CD4+. According to these theories, the thymic epithelial cells and myoid cells which express AChR in their surfaces, are plausible candidates for initial auto-sensitization for T-cells against these receptors. Myoid cells are muscle-like cells who express muscle antibodies as anti-desmin and anti-smooth muscle actin [4, 5]. They are rare in the thymus, haphazardly distributed in the medulla, often near the Hassall's corpuscles, and are sometimes clustered. Many authors are trying to demonstrate their key- role in the pathogenesis of MG and the association MG-thymic enlargement [5-7]. On one hand, myoid cells are the only cells known to express whole AChR out-side muscle. On the other hand, these cells are closely associated with antigen-presenting dendritic cells, helper T cells, B cells in lymphoid follicles. Thus, all the cellular components required to initiate and maintain an autoimmune response to AChR are present in the thymus of patients with MG. In our study, myoid cells were attested to be present by immunohistochemistry (desmin+, smooth muscle actin+) in all cases of thymic enlargement even those without MG. This fact led us suppose that there is a doubt about the real role of myoid cells in the association MG-thymic enlargement (thymolipoma or true thymic hyperplasia).

5. CONCLUSION

Many theories have been stipulated concerning the pathogenesis of the association MG-thymic enlargement. In spite of the multiplicity of the theories concerning this disease, all authors agree about the fact that thymus is the main site of auto-sensitization to AChR. Our results make the role of the myoid cells in this association doubtful and further studies may be useful in order to assess their real role.

Funding: This study received no specific financial support.

Competing Interests: The authors declare that they have no competing interests.

Contributors/Acknowledgement: All authors contributed equally to the conception and design of the study.

REFERENCES

- [1] O. Archer and J. Pierce, "Role of thymus in development of the immune response," *Fed. Proc.*, pp. 20-26, 1961.
- [2] G. Gronseth and R. Barohn, "Practice parameter, thymectomy for auto-immune myasthenia gravis," *Neurology*, vol. 55, pp. 7-15, 2000.
- [3] R. Mantegazza, F. Baggi, P. Bernasconi, C. Antozzi, P. Confalonieri, L. Novellino, L. Spinelli, M. Ferro, E. Beghi, and F. Cornelio, "Video-assisted thoracoscopic extended themectomy and extended transsternal themectomy (T-3b) in non thymomatous myasthenia gravis patients: Remission after 6 years of follow-up," *J Neurol Sci.*, vol. 212, pp. 31-36, 2003.
- [4] A. Marx, A. Willisch, A. Schultz, S. Gattenlohner, R. Nenninger, and H. Hermelink, "Pathogenesis of myasthenia gravis," *Virchows Arch.*, vol. 430, pp. 355-364, 1997.
- [5] J. Pal, C. Rozsa, S. Komoly, and Z. Illes, "Clinical and biological heterogeneity of autoimmune myasthenia gravis," *J Immunoneurol.*, vol. 231, pp. 43-54, 2011.
- [6] S. Ragheb and R. Lisak, "The thymus and Myasthenia gravis," *Chest Surg. Clin. N. Am.*, vol. 11, pp. 311-27, 2001.
- [7] G. Sims, H. Shiono, N. Willcox, and D. Stott, "Somatic hypermutation and selection of B cells in thymic germinal centers responding to acetylcholine receptor in Myasthenia gravis," *Journal of Immunology*, vol. 167, pp. 1935-1944, 2001.
- [8] A. Vincent, "Unravelling the pathogenesis of myasthenia gravis," *Nat Rev Immunol.*, vol. 2, pp. 797-804, 2002.
- [9] A. Wakkach, T. Guyon, C. Bruand, S. Tzarlos, S. Kaminsky, and S. Aknin, "Expression of acetylcholine receptor genes in human thymic epithelial cells: Implication for Myasthenia gravis," *J Immunol.*, vol. 175, pp. 3752-3760, 1996.

BIBLIOGRAPHY

- [1] D. Drachman, "Myasthenia gravis," *N Engl J Med.*, vol. 330, pp. 1797-1810, 1994.

TABLES

Table-1. Clinical, radiological and histological characteristics of the studied population

	Sex/Age (years- old)	Medical history	Computed tomography findings	size (cm)	Study sample	Histologic al diagnosis
1	F/14	Myasthenia gravis	Normal	4	Thymectomy	TL
2	M/48	Diabetes/myasthenia gravis		6	Thymectomy	TTH
3	M/18	Cushing syndrome	Anterior mediastinal mass	8	Thymectomy	TTH
4	M/14	Burkitt lymphoma treated by chemotherapy		6	Surgical Biopsy	TTH
5	F/30	ovarien immature Teratoma treated by chemotherapy + surgery		3.5	Surgical Biopsy	TTH
6	M/24	Cystic Plerurisy		7.5	Thymectomy	TL

F: Female, M: Male, TL: thymolipoma, TTH: true thymic hyperplasia

FIGURES

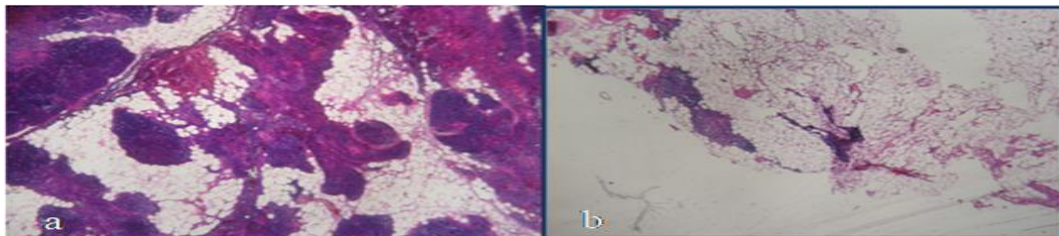


Figure-1. a/ Microscopic findings of true thymic hyperplasia with numerous lobules with well-defined cortical and medullary areas resembling the normal thymus. b/ Microscopic findings of thymolipoma composed of abundant mature fatty tissue with scattered thymic islands including Hassall's corpuscles (HE x 200).

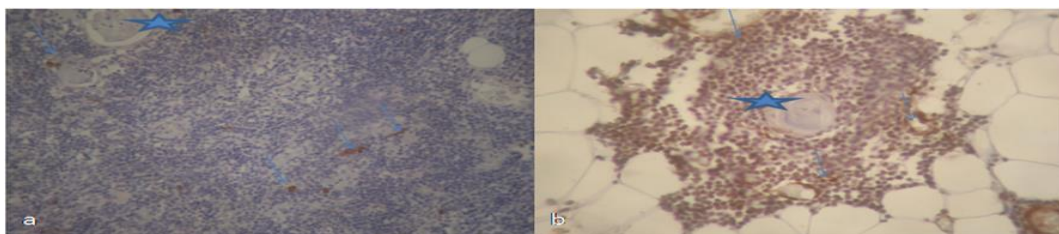


Figure-2. a/ Immuno-histochemical findings showing the expression of Desmin and Smooth muscle Actin by myoid cells (arrow) in true thymic hyperplasia. These spindle cells are mainly medullary situated near Hassall's corpuscles (stars). b/ . Immuno-histochemical findings showing the expression of Desmin and Smooth muscle Actin by myoid cells (arrow) in thymolipoma

Views and opinions expressed in this article are the views and opinions of the author(s), International Journal of Medical and Health Sciences Research shall not be responsible or answerable for any loss, damage or liability etc. caused in relation to/arising out of the use of the content.