



Case Study

A RARE HISTOLOGICAL ENTITY- ORAL FIBROLIPOMA

Priyanka Debta[†] --- F.M. Debta² --- Ruchi Bhuyan³ --- Saswati Siddhartha⁴ --- Prashant Kumar Goyal⁵ --- Sandeep Mohanty⁶

¹Reader, Department of Oral Pathology & Microbiology, I.D.S., BBSR, Odisha, India

²Assistant professor, Department of Oral Medicine & Radiology, S.C.B. Government Dental College. Cuttack, Odisha, India

³Professor, Department of Oral Pathology & Microbiology, I.D.S., BBSR, Odisha, India

⁴Second yr P.G. student, Department of Oral Pathology & Microbiology, I.D.S., BBSR, Odisha, India

⁵Third yr P.G. student, Department of Oral Medicine & Radiology, S.C.B. Government Dental College. Cuttack, Odisha, India

⁶Second yr P.G. student, Department of Oral Medicine & Radiology, I.D.S., BBSR, Odisha, India

ABSTRACT

Among lipoma of oral cavity, fibrolipoma is one of the rare histopathological variant. Intraoral lipomas are rare lesions which may be discovered during routine dental examinations since they present as slow growing, painless and asymptomatic masses. For definite diagnosis histopathological examination plays a significant role in providing successful treatment and preventing any malignant transformation. Prognosis is generally good as recurrence is very rare. Here we present a case of oral fibrolipoma of buccal mucosa.

Keywords: Oral mucosa, Fibrous component, Lipomatous tissue.

Received: 9 September 2016/ Revised: 9 November 2016/ Accepted: 16 November 2016/ Published: 1 December 2016

Contribution/ Originality

This case report is one of the rare presentation of lipoma. So more cases should be documented to make dental professionals aware of its features.

1. INTRODUCTION

Lipoma is a slowly growing neoplasm composed of mature fat cells grouped in lobules by connective tissue septa. WM Abdalla, et al. [1]. Fibrolipoma is one of the subtype of the lipoma. CDM Fletcher, et al. [2]. According to World Health Organization (WHO) fibrolipoma are classified as one of the variant of lipomas and yet now fibrolipoma is very rare in the oral and maxillofacial regions. BS Manjunatha, et al. [3]

Although fibrolipomas are known as benign tumours, long standing and recurrent lipoma can turn into malignant lesion i.e. liposarcoma. MM Chidzonga, et al. [4]. These are slow growing, painless and asymptomatic lesions which may interfere with speech and mastication SN Jung, et al. [5]. We report a case of intraoral fibrolipoma in right buccal mucosa of oral cavity in 50 year old female.

2. CASE REPORT

A patient reported with a chief complaint of growth on right cheek. This old female patient's age was 50 years. There was history of slow continuous gradual enlargement of swelling and it was first noticed 3 years ago. This was associated with difficulty in mastication and deglutition. Intraoral examination revealed a pinkish yellow, well

defined swelling measuring 2.5x1.5 cm, present in right buccal mucosa adjacent to upper second molar region. On palpation the swelling was soft, fluctuant, non tender, mobile and with smooth, slippery margins. A provisional diagnosis of intraoral lipoma was established. Normal findings of blood investigation was found. Under local anaesthesia the lesion was excised and sent for histopathological examination.

Microscopic examination revealed 8-10 layer thick keratinised stratified epithelium with short rete ridges. Underlying connective tissue stroma showing adipocytes (without any atypia) admixed with dense collagenous fibres and fibroblasts. Clinico-pathological examination, suggestive of fibrolipoma. No sign of recurrence seen post operatively during follow up of patient.

3. DISCUSSION

Lipomas are benign soft tissue neoplasms of adipose tissue origin and are relatively less uncommon in the oral cavity, representing about 1% to 5% of all benign oral lesions. ER Fregnani, et al. [6]. Generally oral lipomas have been reported to occur in all ages but are frequently seen after 40 years of age. A Epivatianos, et al. [7]. The metabolism of fat cells in a lipoma is different from normal fat cells, as during starvation, there will be a loss of fat from normal fat deposits in the body, but lipomatous tissue do not show fat loss during starvation and precursors of fatty acid incorporated more rapidly in comparison to normal fat.

Basically, the lipid present in lipoma is not available for metabolism. R Rajeev, et al. [8]. It is most commonly seen in the buccal mucosa and buccal vestibule and it also shows a slight predominance in females. GS Rao, P Kumar and A Naraniya [9, 10].

In our case the tumor was present in a 50 yr old female patient in the right buccal mucosa adjacent to upper second molar tooth region. Microscopically the fibrolipoma is composed of lobules of chicken wire appearing; benign adipocytes with a component comprising broad bands of dense collagen. It is mostly well circumscribed and may be thinly encapsulated like the classic lipoma. P Kumar and Naraniya [10]. Differential diagnosis includes many benign mesenchymal tumors such as fibromas, simple lipomas and minor salivary gland tumors either benign or malignant. M Scivetti, et al. [11]

The proliferative activity of fibrolipoma revealed a greater proliferative rate than other simple variants which indicates the need for accurate diagnosis of such variants with high proliferative activity and further encourages similar studies. Rajeev, et al. [8] furthermore liposarcoma of oral cavity is exceedingly rare, but this entity cannot be distinguished from its benign counterpart at clinical examination. C Saverio, et al. [12]. Thus Histological examination is must and it should be differentiated from malignant features based on the detection of a lack of lobular architecture and most importantly on the presence of multivacuolated adipose cells with indented nuclei (lipoblasts), which are typically present in liposarcoma in variable proportions. P Debta, JC Hatziotis [13, 14]. Surgical excision is the treatment of choice for fibrolipoma, life threatening condition may be due to, obstruction of upper airway by its size as sudden asphyxia death has been reported in a case of oesophageal fibrolipoma. S Gupta and Pathak [15].

After surgical excision lesions located outside the oral cavity show greater recurrence but intraoral intramuscular lipomas although not well limited rarely show recurrence if completely excised. Rajeev, et al. [8]

4. CONCLUSION

Fibrolipoma is a rare lesion so more cases should be documented to make dental professionals aware of its features. Histopathological examination is advised for the confirmation of diagnosis. This would be helpful in providing treatment and prevention of complications such as malignant transformation.

Funding: This study received no specific financial support.

Competing Interests: The authors declare that they have no competing interests.

Contributors/Acknowledgement: All authors contributed equally to the conception and design of the study.

REFERENCES

- [1] W. M. Abdalla, A. C. Da Motta, S. Y. Lin, E. F. McCarthy, and S. J. Zinreich, "Intraosseous lipoma of the left frontoethmoidal sinuses and nasal cavity," *American Journal of Neuroradiology*, vol. 28, pp. 615-617, 2007.
- [2] C. D. M. Fletcher, K. K. Unni, and F. Mertens, *World health organization of tumors*. Lyon, France: IARC Press, 2002.
- [3] B. S. Manjunatha, G. S. Pateel, and V. Shah, "Oral fibrolipoma- a rare histological entity: Report of 3 cases and review of literature," *Journal of Dentistry (Tehran)*, vol. 7, pp. 226-231, 2010.
- [4] M. M. Chidzonga, L. Mahomva, and C. Marimo, "Gigantic tongue lipoma. A case report," *Medicina Oral, Patología Oral y Cirugía Bucal (Internet)*, vol. 11, pp. 437-439, 2006.
- [5] S. N. Jung, J. W. Shin, and H. Kwon, "Fibrolipoma of the tip of the nose," *Journal of Craniofacial Surgery*, vol. 20, pp. 555-556, 2009.
- [6] E. R. Fregnani, F. R. Pires, R. Falzoni, M. A. Lopes, and P. A. Vargas, "Lipomas of the oral cavity: Clinical findings, histological classification and proliferative activity of 46 cases," *International Journal of Oral and Maxillofacial Surgery*, vol. 32, pp. 49-53, 2003.
- [7] A. Epivatianos, A. K. Markopoulos, and P. Papanayotou, "Benign tumors of adipose tissues of the oral cavity. A clinicopathologic study of 13 cases," *Journal of Oral and Maxillofacial Surgery*, vol. 58, pp. 1113-1118, 2000.
- [8] R. Rajeev, V. T. Beena, G. Indu, K. Choudhary, and A. Devu, "Fibrolipoma of floor of the mouth of 20 years of duration," *Clinical Cancer Investigation Journal*, vol. 3, pp. 394-397, 2014.
- [9] G. S. Rao, L. Chatra, and P. Shenai, "Intra-oral lipoma- A rare entity," *International Journal of Anatomy Radiology and Surgery*, vol. 2, pp. 1-3, 2013.
- [10] P. Kumar and A. Naraniya, "Intraoral fibrolipoma: A rare histological variant," *Indian Journal of Oral Sciences*, vol. 3, pp. 39-41, 2012.
- [11] M. Scivetti, M. Di Cosola, L. Lo Muzio, G. P. Piolli, E. Maiorano, and S. Capodiffero, "Giant fibrolipoma of the cheek: Report of a case," *Av Odontostomatol*, vol. 22, pp. 1-3, 2006.
- [12] C. Saverio, M. Eugenio, S. Francesco, and F. Gianfranco, "Fibrolipoma of the lip treated by diode laser surgery: A case report," *Journal of Medical Case Reports*, vol. 2, p. 1, 2008.
- [13] P. Debta, N. Mohanty, S. R. Misra, and D. P. Mandal, "Intraoral fibrolipoma of lower labial mucosa: A rare variant of classic lipoma," *Journal of Odisha Dental Association*, vol. 3, pp. 12-15, 2014.
- [14] J. C. Hatziotis, "Lipoma of the oral cavity," *Oral Surgery, Oral Medicine, Oral Pathology*, vol. 31, pp. 511-524, 1971.
- [15] S. Gupta and S. Pathak, "Fibrolipoma of buccal mucosa- a case report," *Journal of the Indian Dental Association*, vol. 5, pp. 737-738, 2011.

Figure legends:

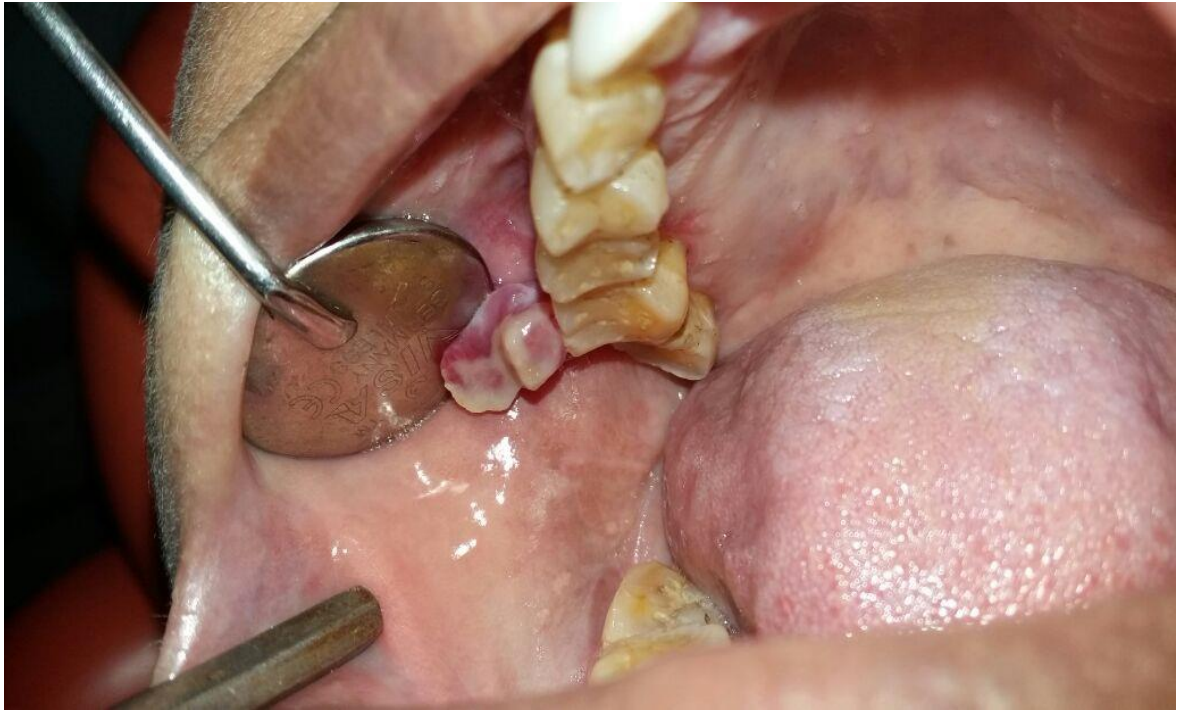


Fig-1. Intraoral pinkish yellow exophytic pedunculated growth on right buccal mucosa.

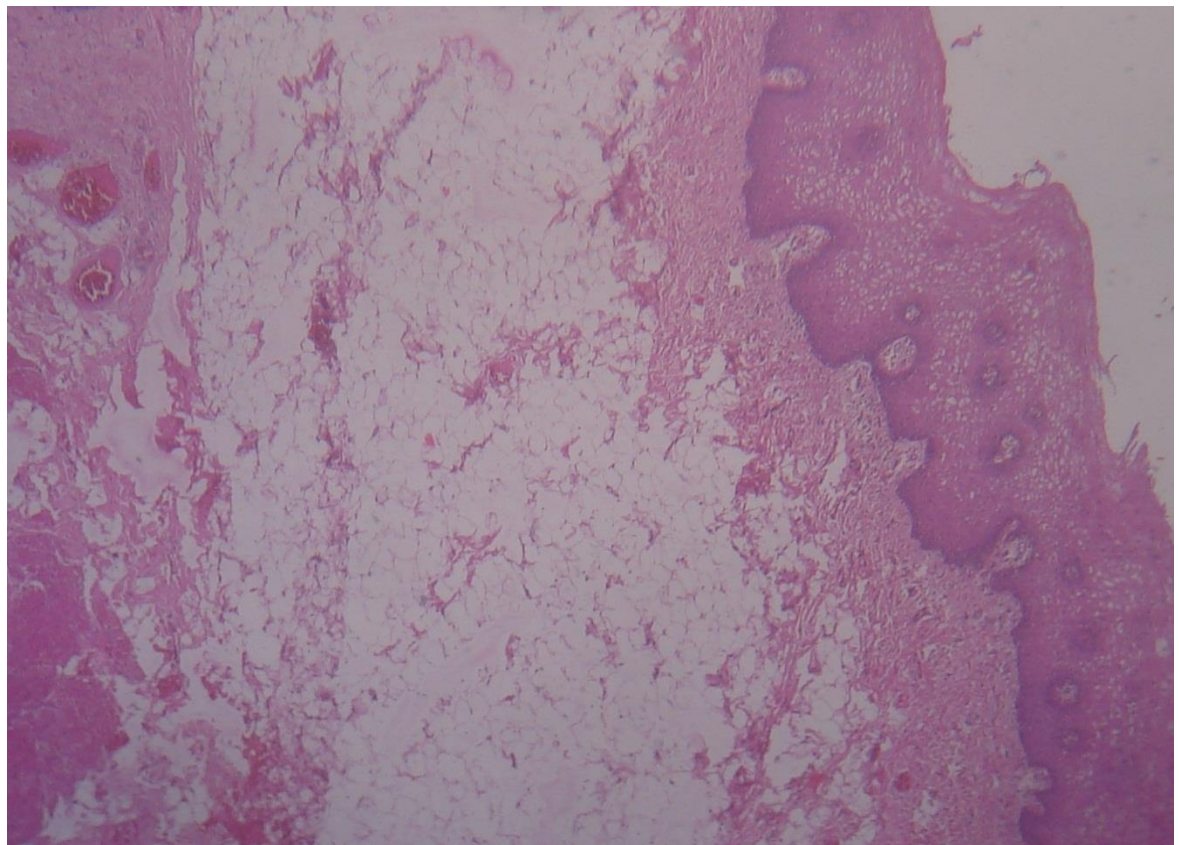


Fig-2. Keratinised stratified squamous epithelium and collagen fibres along with adipose tissue (H & E , X4).

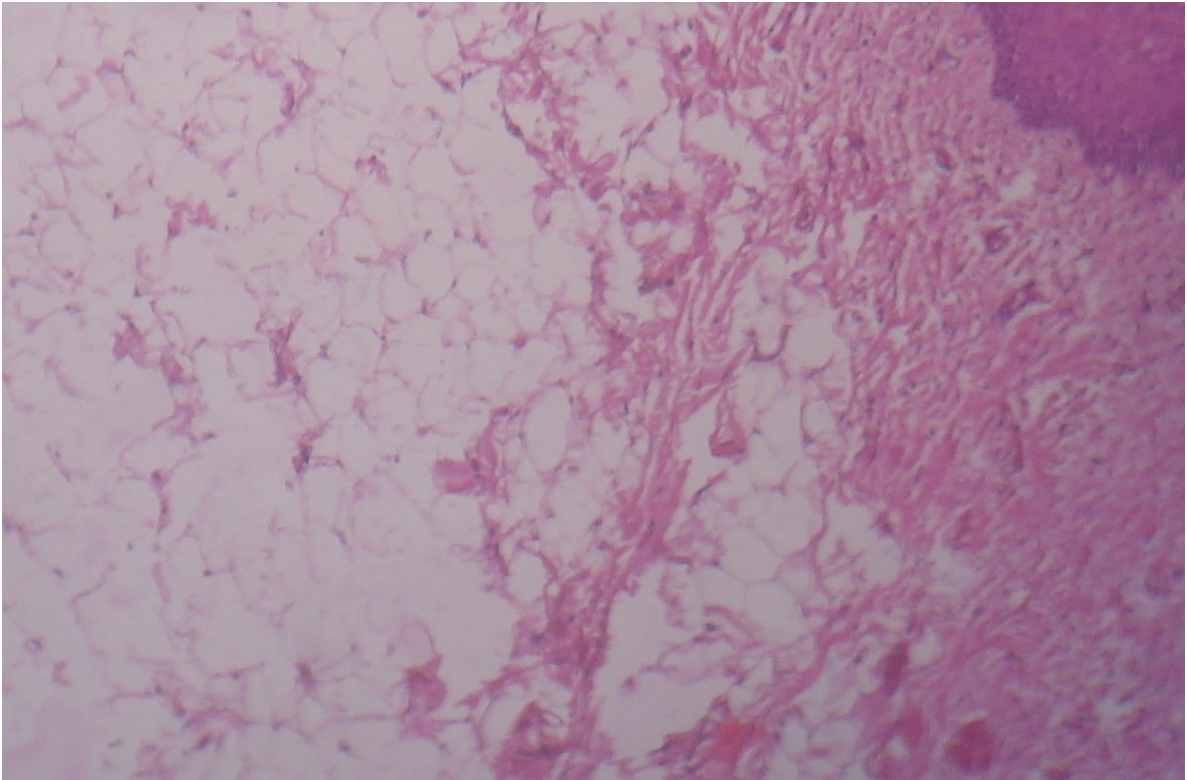


Fig-3. Mature adipocytes admixed with numerous collagen fibres (H & E, X10).

Views and opinions expressed in this article are the views and opinions of the author(s), International Journal of Medical and Health Sciences Research shall not be responsible or answerable for any loss, damage or liability etc. caused in relation to/arising out of the use of the content.