

## Animal Review

2018 Vol. 5, No. 2, pp. 12-21

ISSN(e): 2409-6490

ISSN(p): 2412-3382

DOI: 10.18488/journal.ar.2018.52.12.21

© 2018 Conscientia Beam. All Rights Reserved.



# THE POTENTIAL EFFECT OF ZINC DEFICIENCY ON REPRODUCTIVE PROFILE OF MALE RAT AND ITS POSSIBLE CONSEQUENCES

**Aamir Nawab<sup>1</sup>**  
**Yi Zhao<sup>2</sup>**  
**Fahar Ibtisham<sup>3</sup>**  
**Guanghui Li<sup>4</sup>**  
**Mei Xiao<sup>5</sup>**  
**Jiang Wu<sup>6</sup>**  
**Wenchao Liu<sup>7</sup>**  
**Shuyan Tang<sup>8</sup>**  
**Lilong An<sup>9\*</sup>**

<sup>1</sup>Department of Veterinary Medicine, Agricultural College, Guangdong Ocean University, Zhanjiang 524088, Guangdong, China; Faculty of Veterinary Medicine, PMAS Arid Agriculture University Rawalpindi, Pakistan

<sup>2</sup>Email: [Aamir94@qq.com](mailto:Aamir94@qq.com)

<sup>3,5,6,7,8,9</sup>Department of Veterinary Medicine, Agricultural College, Guangdong Ocean University, Zhanjiang 524088, Guangdong, China

<sup>4</sup>Email: [1250042754@qq.com](mailto:1250042754@qq.com)

<sup>5</sup>Email: [fahar1992@qq.com](mailto:fahar1992@qq.com)

<sup>6</sup>Email: [yiao0812@126.com](mailto:yiao0812@126.com)

<sup>7</sup>Email: [wujiang462913@126.com](mailto:wujiang462913@126.com)

<sup>8</sup>Email: [wenchao2011@hotmail.com](mailto:wenchao2011@hotmail.com)

<sup>9</sup>Email: [849589013@qq.com](mailto:849589013@qq.com)

<sup>\*</sup>Email: [anlilong@126.com](mailto:anlilong@126.com)

<sup>1</sup>Department of Animal Science, Agricultural College, Guangdong Ocean University, Zhanjiang 524088, Guangdong, China

<sup>\*</sup>Email: [guanghui0121@126.com](mailto:guanghui0121@126.com)



(+ Corresponding author)

## ABSTRACT

### Article History

Received: 9 August 2018

Revised: 13 September 2018

Accepted: 17 October 2018

Published: 19 November 2018

### Keywords

Zn deficiency

Testes

Spermatogenesis

Luteinizing hormone

Sperm physiology

Male rats

Zinc (Zn) has antibacterial and antifungal properties, so, it is being widely used in food and pharmaceutical industries. Transition metal especially Zn deficiency has deleterious effects all over the world due to wide consumption of Zn deficient food byproduct. Several studies have reported that transition elements especially Zinc deficiency affects the endocrine and reproductive system. This overview comprises the information about negative effects of Zn deficiency on reproductive system of male rat and their possible outcomes. Scientific studies indicated that Zn deficiency severely affects the reproductive physiology of male rats. Zn deficiency suppresses the function of male rat testes inclosing spermatogenesis and steroidogenesis by reducing the production of androgen hormone. In addition, Zn deficient rats also indicated testicular atrophy, primary and secondary spermatogonial stem cells disruption, lower number of sperm cells count, sperm quality, motility, viability, enhance in oxidative stress, inhibition of Testosterone (T) level which, in turn may cause infertility. The different consequences in animal models by zinc application are dose and duration dependent. Several studies propose that both higher and lower Zn concentration can effects the rat reproductive function. Therefore, the available outcomes revealed that Zn deficiency might have significant influence on luteinizing hormone and follicle stimulating hormone affecting the sperm physiology and histology in certain tissues.

**Contribution/Originality:** This recent study has contributed significant scientific information on a particular subject area “Zinc deficiency”. A lot of reports have discussed the Zinc and its effects on human but there is lack of sufficient data related to Zn deficiency on reproductive profile of male rats. Therefore, this study is one of very few studies which have documented that Zinc is necessary in male reproductive system of human and animals. On the other side, it is recommended that optimum amount of Zinc supplementation should be used to avoid the deleterious effects on male reproductive physiology.

## 1. INTRODUCTION

Human, animal and aquatic lives are exposed to certain metals, through different sources. Some of these metals and their oxide are lethal to health inclosing reproductive health and few are important in trace quantity for numerous physiological functions of the body. In 1746, Zinc (Zn) was discovered by German chemist and it is reported as the second most abundant transition metal in the animal body and it is the only element which seems in all enzyme classes [1]. It cannot be synthesis in the body [2] and needs daily dietary intake to meet the physiological requirements. Zn importance has been recognized many years ago. In biological system, It plays structural, regulatory or catalytic roles in more than 200 enzymes [3]. Zn is an essential element of unique biologic and public health significance [4]. Zn as an important mineral is essential for animals [5] plants [6] and microorganisms [7].

It is reported that Zn is necessary for immune function, DNA replication, RNA polymerases and some other metabolic processes [4]. Another structural role of Zn is in protein synthesis, cell replication and growth processes. Zn is necessary for testicular maturation, wound healing, immunocompetence and neurological function [8]. It is also required for reproduction [9] gene expression [10] ossification [10] photochemical procedures of vision [11] and antibody production [12]. In addition, Zn is counted in many nutritional supplements [13]. Studies reported that Zn is also required for normal condition of epidermis, epithelium, skin and hooves [14]. Another study reported that in mammalian genomes about 3 to 10 % of all proteins are considered to bind zinc for holding, activity and conformational changes [15].

In 1934, first time it was reported that Zn was essential for normal growth in rats [16]. After 25 year, some authors reported that Zn deficiency were detected in chicks hatched from hens, fed Zn-deficient (ZD) diets and were died 4 days after birth [17]. The chicks were described by various skeletal defects and structural abnormalities of brain [18]. Several authors [19] stated that rats fed a Zn-deficient (ZD) feed had a fewer live fetuses/litter, and were low body weight, and several skeletal and soft tissues anomalies [19]. There were common abnormalities of development, deformities of the brain, lungs, heart, and urogenital system. In addition, it comprised the misshaped heads and fused or misplaced digits of the feet.

Zn deficiency has been recognized in small laboratory animals, domestic animals, minks, and monkeys. Zn deficiency in mammals reported reduced food intake, growth retardation, testicular atrophy, swelling of feet, skin lesions, hair loss and hindered reproduction [18, 20]. Another study in human reported that chronic Zn deficiency is connected with immature testes, delayed sexual maturity, lack of appetite, immunosuppression, dwarfism, night blindness, spleen and liver abnormalities, reduced secretion of luteinizing hormone (LH) and folate deficiency [14, 21, 22].

On the other hand, Zn is thought to be an important ingredient in male reproductive system of the human and animals. Therefore, the aim of this review was to analyze the effect of Zn deficiency on reproductive profile of male rat and their promising consequences.

### 1.1. Zn Deficiency and its Adverse Effects

The surprising increase in the demand of Zn is mostly ascribed due to its superior antibacterial properties [22]. It has been reported that due to antimicrobial properties Zn is being utilized in the food industry as packaging and additives agent [23]. On the other hand, Zn deficiency has been documented in humans and a wide range of animals (Table 1). It shows severe effects on all phases of growth and male reproductive system in an adult. In marine invertebrates, Zn plays a significant role in pH regulation of sperm. A report of semen examination described that Zn deficiency less than 6.5 µg/L badly affected sperm motility and pH in horseshoe crab (*Limulus polyphemus*), sea urchins (*Strongylocentrotus purpuratus*), and starfish [7]. Zn deficiency causes injurious effects on esophagus, kidney, bone and testes of rats, and it is reported that in bone and plasma, alkaline phosphatase (ALP) activity is reduced in ZD pigs, cows and rats [22, 24].

Table-1. Effects of Zn deficiency on different species

Species	Organs	Dose	Toxicity	Reference
Mouse	Reproduction	1.5 and 2.5 g/100 mL Zinc sulfate (ZnSO <sub>4</sub> )	Reduced sperm count and motility, spermatoc arrest. Affect the seminiferous tubules and fibrosis in interstitial tissue	Nicholas and Caldart [22]
Rat	Reproduction	7.50-15 and 30 mg/kg BW daily Zinc chloride (ZnCl <sub>2</sub> )	Decreased sperm count and viability	Dissanayake, et al. [25]
Human	Reproduction	0.5 mg/kg BW daily	Zn have inverse relationship with testosterone (T) production	Manzoor, et al. [26]

Source: Kumari, et al. [27]

Zn deficiency is associated with abnormal testicular function in humans and animals and appears to be necessary for spermatogenesis and sperm production [27]. An adult male fed ZD diet, reported testicular lesions and decreased weight of male accessory sex gland [18]. Hypogonadism and testicular atrophy is reported in ZD rats and it causes the spermatoc arrest, atrophy of seminiferous tubules and interstitial cells, decreased testosterone (T) levels and serum testicular Zn concentrations [28]. In Leydig cells, Zn is necessary for normal testosterone metabolism. Calcitonin hinders flow of Zn in the isolated rat Leydig cell, but these sound effects take more than 2 days and are reported only in Zn deficiency [6]. During maturity of rats, Zn deficiency reduces the action of dipeptidyl carboxypeptidase (Dcp) enzyme in the testes and epididymis; this Dcp is essential for maturation of sperm cells and decreased activity of Dcp may cause delay in sexual maturity [29].

The literature findings demonstrated that both Zn higher and lower concentration may act as testicular toxicant in mice [30]. But, it also has been observed that excess dietary Zn may cause subnormal growth, anemia and reproductive failure in rats.

### 1.2. Effect on Male Reproductive System

Nutritional status plays an energetic role in human and animal reproduction (Table 2). There are some trace elements especially Zn is considered an essential ingredients for the optimal performance and normal productivity in male reproductive system. Hypogonadism is noticeable characteristic of severe Zn deficiency detected in the young and growing male rats [5]. In 1961 and 1963, Prasad reported the first case of Zn deficiency in humans [22, 31]. Hypogonadic dwarfism was recorded in Iranian and Egyptian children. Prasad proved that this was due to Zn deficiency. Another study reported that mild Zn deficiency causes the oligospermic sterility and inability in rats and men. These effects have been observed in subjects with drepanocytosis [32] and dialyzed uremia [5]. Several authors examined that oligospermia was observed in 4/5 men on a limited 30-week diet containing only 4 mg of Zn [24]. In all these anomalies, it is detected that ZD diet below the average supplementation has deleterious effects on reproductive profile of human and male rats.

Table-2. Role of Zn in Spermatogenesis

Phase of Spermatogenesis	Role of Zn	Reference
Initial phase of spermatogenesis	Role in ribonuclease (RNase) reaction	Cuevas and Koyanagi [5]
Medium phase of spermatogenesis	Spermatozoa development and role in preservation of germinal epithelium and seminiferous tubule	Cuevas and Koyanagi [5]
Final phase of spermatogenesis	Increase sperm motility	Cuevas and Koyanagi [5]

Source: Cuevas and Koyanagi [5]

### 1.3. Effect on Testicular Growth

The testicles have main role in sperm production (Table 3). The seminiferous tubules are considered as the structural and functional unit of testicles and weight of testes depends on the number of seminiferous tubules. Fertility is highly associated with testicles size and poor fertility often being linked with small testicles, because the process of spermatogenesis take place in the seminiferous tubules and less testicles weight is considered due to lower number or length of seminiferous tubules [33].

**Table-3. Function of male reproductive system**

Male reproductive organs	Function	Reference
Testes	Testosterone (T) production	Ibtisham, et al. [21]
Epididymis (caput, corpus and cauda)	Sperm development, storage and motility	Ibtisham, et al. [21]
Vas deferens, accessory sex glands and penis	Sperm ejaculation into vagina (female reproductive tract)	Ibtisham, et al. [21]

Source: Ibtisham, et al. [21]

It is reported that in rats Zn deficiency decreases the diameter of seminiferous tubules and also both the basal and luminal areas. Severe atrophic variations in spermatogenic cells has been described in ZD animal and deterioration of the cellular layer of the seminiferous tubules [13]. According to previous literature, ZD rats may cause the decrease in tubular diameter and decrease in the number of germinal cells and Sertoli cells. In rats [26] and men [5] Zn deficiency has been found to be associated with low testosterone (T) levels. In rats, testicular atrophy was recorded due to Zn deficiency [5]. In rats and boars, Zn deficiency may involve in decreasing the growth and development of accessory sex glands. Scrotal size has been shown to be correlated to testicular weight and testicular weight has also been associated to sperm production [23]. Taken together, In ZD rats, it has been found that there is an obvious decrease in testosterone (T) levels, seminiferous tubular diameter and in the weight of male sex organs.

### 1.4. Effect on Spermatogenesis

Previous studies in hypophysectomized rats clearly explained that follicle stimulating hormone (FSH) and T are main factors for the regulation of spermatogenesis [34]. FSH requires for the development of the undeveloped testes by proliferation of Sertoli cells and later development of A and B spermatogonial stem cells [6]. T alone can play an important role in spermatogenesis, but the synergistic role of FSH is essential to stabilize the characteristics of spermatogenesis [34].

Zn deficiency impairs the process of spermatogenesis by different pathways. It has been reported that in testes of rats, Zn deficiency has been linked with testicular atrophy, destruction of testicular cells and testicular function of steroidogenesis [4]. Zn deficiency also has been associated with low T level, which provides a strong proof that Zn plays a key role in the production of T, because T is produced and secreted from Leydig cells, so Zn deficiency may be involve in apoptosis of the Leydig cells. T is considered an important hormone for spermatogenesis. As a result, in primary stages of spermatogenesis, Zn deficiency may be linked with apoptosis of testicular cells, as well as spermatocyte maturation phase, causing impairment in the late phase of spermatogenesis [33].

Another study reported that increased oxidative stress, high serum malondialdehyde (MDA) and high tumor necrosis factor-alpha (TNF- $\alpha$ ) and low levels of total antioxidant activity, serum superoxide dismutase (SOD) and alpha-tocopherol was associated in ZD animals. Some factors that incidentally increase the oxidative stress by reducing the capacity of cells to resist oxidation will also causes the apoptosis [35]. In light microscopy, Zn deficiency has described the spermatogenic arrest at the phase of round and elongated spermatids. This displays that high lipid peroxidation hinder the consequence of spermatogenesis, as confirmed by microscopic examination of apoptosis in the Sertoli cell linked with oxidative stress and Zn deficiency.

It has been reported in rat study, that Zn deficiency is associated with stress and elevated cortisol levels. Stress can affect the spermatogenesis due to variable T secretion. A new invented gonadotropin-inhibitory hormone has an inhibitory effect on the hypothalamic–pituitary gonadal axis (Fig. 1). Decrease in T levels has been reported due to inhibition of the hypothalamic–pituitary gonadal axis, which may causes the variations in Sertoli cells and tightest barrier (blood-testis barrier), as a result which may affects the spermatogenesis.

Therefore, due to Zn deficiency, oxidative stress, apoptosis and reduced T production is connected with impaired process of spermatogenesis. These outcomes propose that Zn deficiency influence the reproductive system of male rats.

### 1.5. Effect on Sperm Morphology

The main factor in the semen examination is the sperm morphology. Sperm motility plays a fundamental role in the fertilization, because abnormal sperm impaired the fertility and leading conception more difficult. Zn is considered an important ingredient in the quality; quantity and growth of sperm, but their deficiency produce several sperm morphological abnormalities.

Zn deficiency causes the reduction of T [5] and may also involve in the degenerative variations. A recent study reported that abnormal morphology is due to proliferation of the axonemedense fibre-mitochondria complexes. In rats, the same variation was found after Fe treatment [13]. In rats testes, high Fe content and lipid peroxidation was recorded due to Zn deficiency [36]. Hence, this structural variation can be described by high oxygen free radicals formation, which is induced by Fe [7].

Another study detected that structural abnormalities are due to irregular arrangement of outer dense fibres (ODF) like uncoiling and flattening shape (fig 2). These abnormalities were not present in Fe-treated rats testes. 90% of the sperm Zn is attach to SH-groups of ODF [37]. Thus, due to Zn deficiency, Zn may be detached from SH-groups of ODF followed by their structural alteration leading to uncoiling and flattening. In addition, ODF consist of two [37] or more than two proteins [36] with diverse molecular mass and amino acid composition. The proteins are connected by SS-bond and display a keratin-like structure [37]. ODF may provide elasticity in sperm circulation [37] and may provide safety in mammalian sperm against impairment [38]. The uncoiled and flattened dense fibres in Zn deficiency may also considered as functionally damaged.

From clinical point of view, these results have more importance. Infertile men show a high quantity of sperm with abnormally developed ODF [36] and orally Zn intake has enhanced sperm motility in infertile men with astenospermia and oligospermia [39]. But, in another research this outcome of Zn treatment was not observed [20]. In male, sperm morphology exhibited a minor increase in round sperm head due to Zn deficiency [23]. Sperm with increased axonemedense fibre-mitochondria complexes were not explained. But, it is detected that it may be due to mild Zn deficiency [23] or abnormal sperm which were reduced during maturation and so could not be seen.

A similar study showed that essential fatty acid composition is influenced by Zn deficiency in rats testes. This altered fatty acid may involve in reduction of testicular function, spermatogenesis and androgenesis. These results suggest that Zn deficiency linked with abnormal testicular function is followed by alterations in membrane fatty acid composition, and thus affects the sperm integrity. However, the specific function of this process is remained unclear. It is thought that it can be due to arrested spermatogenesis or testicular necrosis. Additionally, abnormal sperm motility was found in the Japanese eel and goat due to decreased Zn concentration in feed [11, 40]. Sertoli and Leydig cells showed insignificant morphological changes. In control study, rats testes did not show any morphological changes.

### 1.6. Effect on Histopathology

The testes are the main organs of the male reproductive system. They consist of seminiferous tubules, Sertoli cells and Leydig cells [41]. In the presence of luteinizing hormone (LH), Leydig cells are responsible for production

of androgen, like testosterone (T). FSH involves in the development of the immature testis by proliferation of Sertoli cell and later spermatogonial stem cells [7]. T alone can play an important role in spermatogenesis, but the synergistic role of FSH is essential to normalize the process of spermatogenesis [35, 42].

Deficiency of Zn has negative effect on the reproductive profile of humans and animals and it is an enormous problem to nutritionist. Normal histology of testes depends on normal testicular functions (spermatogenesis and steroidogenesis). In histopathological examination, it has been reported that ZD rat presented a number of abnormalities, compared to control group [41] which may affect sperm physiology.

A study on ZD rat showed cytological degenerative changes in germ cells of seminiferous tubules, leading to less number of germ cell, sertoli cells, interstitial cells, primary and secondary spermatogonia, and spermatocytes (sperm cells). Histological study carried by Ashrafi, et al. [3] reported that Zn deficiency in rats, explained the atrophy of seminiferous tubules in some ZD rats. An 8-week feeding trials have been conducted, containing a total of 22 ZD (Zn-deficient) and 19 ZC (Zn-control) male rats.

In histological examination, the testes of rats after 8-weeks on ZD diet again verified the previous results of several authors [3]. Complete or Partial degeneration of the germ cells epithelium had examined in 17/22 rats. It was clear that the matured testes composed of healthy tubule and consists of a less number of sperms in the epididymis. Apparently healthy but immature testicular tissue was present in 3 ZD rats and the remaining 2 exposed all degenerative phases of spermatogenesis. However, one of these, which was recently matured were examined no sperms in the epididymis. The other numerous sperms were present in the epididymis were less than the controls group. Normal mature testes including the large numbers of sperms in the epididymis was recorded in control rats. In all ZD rats, the interstitial cells were detected in the testes, except for reduced size, but looked normal. In ZD rats, decreased size of epithelial layer, small acini, less secretion were observed in all accessory sex organs but no additional pathological variations were detected in these tissues. In ZD rats, the dorsolateral prostate glands associated to Zn- specific stain were negative or slightly positive.

In the control groups, the lateral edges of the glands revealed a clear positive reaction. In ZD rats, gonadotrophs and thyrotrophs were characterized in pituitary glands stained with a glycoprotein stain compared with the control groups. In ZD rats, testes demonstrated atrophy of the tubular epithelium. Taken together, ZD group influence the male reproductive system of the rats and cause the reduction in all sex organs, testicular atrophy, clear atrophy of the tubular epithelium, and reduced Zn concentrations in testes, epididymis, and dorsolateral prostate glands.

## 2. CONCLUSION

The overall consequences of this overview provide a confirmation that certain essential elements especially Zn deficiency may affect the male rat reproductive system inclosing the function of spermatogenesis, sperm motility, secretion of accessory glands, fertility, T-level and antioxidant defense system. Experimental studies on rats explained that Zn deficiency depends on dose and time duration and their effects are also variable. The available data reported that 5 mg/day per rat Zn supplementation is considered as optimum level without causing any harmful effects on libido and sexual ability of male rats. Therefore, it is recommended that optimum amount of Zinc supplementation should be used to avoid the deleterious effects on male reproductive physiology.

### Abbreviation

Zn; Zinc, T; Testosterone, FSH; Follicle stimulating hormone, LH; Luteinizing hormone, ZD; Zinc deficient, ZC; Zinc control, ALT; Alanine aminotransferase, ALP; Alkaline phosphatase, LDH; Lactate dehydrogenase, ZnO nP; Zinc oxide nanoparticle, ZnO mP; Zinc oxide microparticle, MDA; Malondialdehyde, TNF- $\alpha$ ; Tumor necrosis factor-alpha, SOD; Serum superoxide dismutase, GnIH; Gonadotropin-inhibitory hormone, HPG; hypothalamic-

pituitary gonadal, ODF; Outer dense fibres, ZnCl<sub>2</sub>; Zinc chloride, ZnSO<sub>4</sub>; Zinc sulfate, Fe; Iron, SH; Sulfhydryl, S-S bond; Disulfide bond, DCP; Dipeptidyl carboxypeptidase

**Funding:** This study received no specific financial support.

**Competing Interests:** The authors declare that they have no competing interests.

**Contributors/Acknowledgement:** Special thanks to Animal Review Journal for giving an opportunity to share knowledge on Zinc deficiency and its possible consequences on male rats reproductive system and strategies to overcome this problem. The author wish to thank beloved parents (Rana Nawab Ahmad and Mrs. Sultana), grandparents (Saith Bachal Din), uncle (Rana Maqbool Ahmad) and brother (Rana Kashif Nawab) for continued support and excellent mentorship.

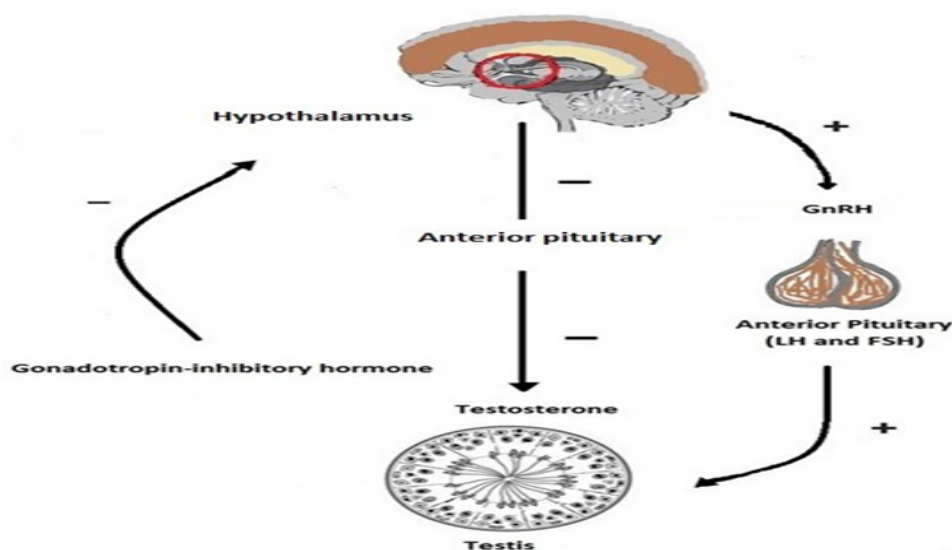
## REFERENCES

- [1] M. R. Shahraki, T. Forghani, M. Mohammadi, and A. Khazaei-Feizalabad, "The effect of intraventricular administration of zinc on serum LH, FSH, prolactin and testosterone in male rats," *Zahedan Journal of Research in Medical Sciences*, vol. 17, pp. 29–32, 2015. Available at: <https://doi.org/10.17795/zjrms-1059>.
- [2] M. I. Yattoo, A. Saxena, P. M. Deepa, B. P. Habeab, S. Devi, R. S. Jatav, and U. Dimri, "Role of trace elements in animals : A review," *Veterinary World*, vol. 6, pp. 963–967, 2013.
- [3] S. H. Ashrafi, J. Meyer, and C. A. Squier, "Effects of zinc deficiency on the distribution of membrane-coating granules in rat buccal epithelium," *Journal of Investigative Dermatology*, vol. 74, pp. 425–432, 1980. Available at: <https://doi.org/10.1111/1523-1747.ep12544599>.
- [4] B. Halliwell and J. M. C. Gutteridge, "Role of free radicals and catalytic metal ions in human diseases: An overview," *Methods in Enzymology*, vol. 186, pp. 1-85, 1990. Available at: [https://doi.org/10.1016/0076-6879\(90\)86093-b](https://doi.org/10.1016/0076-6879(90)86093-b).
- [5] L. E. Cuevas and A. Koyanagi, "Zinc and infection: A review," *Annals of Tropical Paediatrics*, vol. 25, pp. 149-160, 2005.
- [6] C. J. Biochem, P. Downloaded, and S. Diego, "The effects of dietary zinc deficiency on the reproductive system of male rats1 preparation of diet," *Journal of Biochemistry and Physiology*, vol. 36, 1958.
- [7] C. Y. Cheng and D. D. Mruk, "The blood-testis barrier and its implications for male contraception," *Pharmacological Reviews*, vol. 64, pp. 16-64, 2011. Available at: <https://doi.org/10.1124/pr.110.002790>.
- [8] L. M. Plum, L. Rink, and H. Haase, "The essential toxin: Impact of zinc on human health," *International Journal of Environmental Research and Public Health*, vol. 7, pp. 1342-1365, 2010. Available at: <https://doi.org/10.3390/ijerph7041342>.
- [9] H. Takihara, M. J. Cosentino, and A. Cockett, "Zinc sulfate therapy for infertile male with or without varicocelectomy," *Urology*, vol. 29, pp. 638-641, 1987. Available at: [https://doi.org/10.1016/0090-4295\(87\)90111-7](https://doi.org/10.1016/0090-4295(87)90111-7).
- [10] A. Omu, M. Al-Azemi, M. Al-Maghrebi, C. Mathew, F. Omu, E. Kehinde, J. Anim, M. Oriowo, and A. Memon, "Molecular basis for the effects of zinc deficiency on spermatogenesis: An experimental study in the Sprague-dawley rat model," *Indian Journal of Urology*, vol. 31, pp. 57-57, 2015. Available at: <https://doi.org/10.4103/0970-1591.139570>.
- [11] B. L. Vallee and A. Galdes, *The metallobiochemistry of zinc enzymes. In Advances in Enzymology and Related Areas of Molecular Biology*: John Wiley & Sons, Inc, 2006.
- [12] R. K. Sharma, F. F. Pasqualotto, D. R. Nelson, J. A. J. Thomas, and A. Agarwal, "The reactive oxygen species — total antioxidant capacity score is a new measure of oxidative stress to predict male infertility," *Human Reproduction*, vol. 14, pp. 2801–2807, 1999. Available at: <https://doi.org/10.1093/humrep/14.11.2801>.
- [13] S. A. Hamdi, O. I. Nassif, and M. S. M. Ardawi, "Effect of marginal or severe dietary zinc deficiency on testicular development and functions of the rat," *Archives of Andrology*, vol. 38, pp. 243–253, 1997. Available at: <https://doi.org/10.3109/01485019708994883>.
- [14] A. T. Khan, T. C. Graham, L. Ogden, S. Ali, Salwa, S. J. Thompson, K. F. Shireen, and M. Mahboob, "A two-generational reproductive toxicity study of zinc in rats," *Journal of Environmental Science and Health Part B*, vol. 42, pp. 403-415, 2007. Available at: <https://doi.org/10.1080/03601230701312795>.

- [15] S. H. Lee, J. E. Pie, Y. R. Kim, H. R. Lee, S. W. Son, and M. K. Kim, "Effects of zinc oxide nanoparticles on gene expression profile in human keratinocytes," *Molecular & Cellular Toxicology*, vol. 8, pp. 113–118, 2012. Available at: <http://dx.doi.org/10.1007/s13273-012-0014-8>.
- [16] P. L. Kimmel, D. W. Watkins, E. B. Teller, R. Khanna, S. Dosa, and T. M. Phillips, "Zinc balance in combined zinc deficiency and uremia," *Kidney International*, vol. 33, pp. 1091–1099, 1988. Available at: <https://doi.org/10.1038/ki.1988.116>.
- [17] D. I. Thurnham, "Micronutrients and immune function: Some recent developments," *Journal of Clinical Pathology*, vol. 50, pp. 887–891, 1997. Available at: <https://doi.org/10.1136/jcp.50.11.887>.
- [18] C. D. Hunt, P. E. Johnson, J. Herbel, and L. K. Mullen, "Effects of dietary zinc depletion on seminal volume and zinc loss, serum testosterone concentrations, and sperm morphology in young men," *The American Journal of Clinical Nutrition*, vol. 56, pp. 148–157, 1992. Available at: <https://doi.org/10.1093/ajcn/56.1.148>.
- [19] N. Roohani, R. Hurrell, R. Kelishadi, and R. Schulin, "Zinc and its importance for human health: An integrative review," *Journal of Research in Medical Sciences: The Official Journal of Isfahan University of Medical Sciences*, vol. 18, pp. 144–157, 2013.
- [20] M. Hidiroglou and J. E. Knipfel, "Zinc in mammalian sperm: A review," *Journal of Dairy Science*, vol. 67, pp. 1147–1156, 1984. Available at: [https://doi.org/10.3168/jds.s0022-0302\(84\)81416-2](https://doi.org/10.3168/jds.s0022-0302(84)81416-2).
- [21] F. Ibtisham, A. Nawab, Y. Zhao, G. Li, M. Xiao, and L. An, "Pharmaceutica analytica acta effect of antimicrobial triclosan on reproductive system of male rat," *Pharmaceutica Analytica Acta*, vol. 7, pp. 7–12, 2016. Available at: <https://doi:10.4172/2153-2435.1000516>.
- [22] A. A. Nicholas and C. C. Caldart, "The control of reproductive hazards in the workplace: A prescription for prevention," *Berkeley Journal of Employment & Labor Law*, vol. 7, pp. 523–563, 1983.
- [23] S. Das and A. Green, "Zinc in crops and human health," *Biofortification of Food Crops*, vol. 11, pp. 31–40, 2016.
- [24] N. M. Rabeh and H. A. El-Ghandour, "Effect of iron, zinc, vitamin e and vitamin C supplementation on thyroid hormones in rats with hypothyroidism," *International Journal of Nutrition and Food Sciences*, vol. 5, pp. 201–210, 2016. Available at: <https://doi.org/10.11648/j.ijnfs.20160503.18>.
- [25] D. Dissanayake, P. Wijesinghe, W. Ratnasooriya, and S. Wimalasena, "Relationship between seminal plasma zinc and semen quality in a subfertile population," *Journal of Human Reproductive Sciences*, vol. 3, pp. 124–128, 2010. Available at: <https://doi.org/10.4103/0974-1208.74153>.
- [26] U. Manzoor, S. Siddique, R. Ahmed, Z. Noreen, H. Bokhari, and I. Ahmad, "Antibacterial, structural and optical characterization of mechano-chemically prepared ZnO nanoparticles," *PloS One*, vol. 11, p. e0154704, 2016. Available at: <https://doi.org/10.1371/journal.pone.0154704>.
- [27] D. Kumari, N. Nair, and R. S. Bedwal, "Journal of trace elements in medicine and biology effect of dietary zinc deficiency on testes of wistar rats: Morphometric and cell quantification studies," *Journal of Trace Elements in Medicine and Biology*, vol. 25, pp. 47–53, 2011. Available at: <http://dx.doi.org/10.1016/j.jtemb.2010.11.002>.
- [28] W. M. Elsaed and H. A. Mohamed, "Dietary zinc modifies diabetic-induced renal pathology in rats," *Renal Failure*, vol. 39, pp. 246–257, 2017. Available at: <https://doi.org/10.1080/0886022x.2016.1256321>.
- [29] L. B. Smith and W. H. Walker, "The regulation of spermatogenesis by androgens," *Seminars in Cell & Developmental Biology*, vol. 30, pp. 2–13, 2014. Available at: <https://doi.org/10.1016/j.semcd.2014.02.012>.
- [30] P. I. Oteiza, M. S. Clegg, and C. L. Keen, "Short-term zinc deficiency affects nuclear factor-κB nuclear binding activity in rat testes," *The Journal of Nutrition*, vol. 131, pp. 21–26, 2001. Available at: <https://doi.org/10.1093/jn/131.1.21>.
- [31] G. E. Olson and D. W. Sammons, "Structural chemistry of outer dense fibers of rat sperm' proteins," *Biology of Reproduction*, vol. 22, pp. 319–332, 1980. Available at: <https://doi.org/10.1095/biolreprod22.2.319>.
- [32] H. Najafzadeh, S. Ghoreishi, B. Mohammadian, E. Rahimi, M. Afzalzadeh, M. Kazemivarnamkhashti, and H. Ganjealidarani, "Serum biochemical and histopathological changes in liver and kidney in lambs after zinc oxide

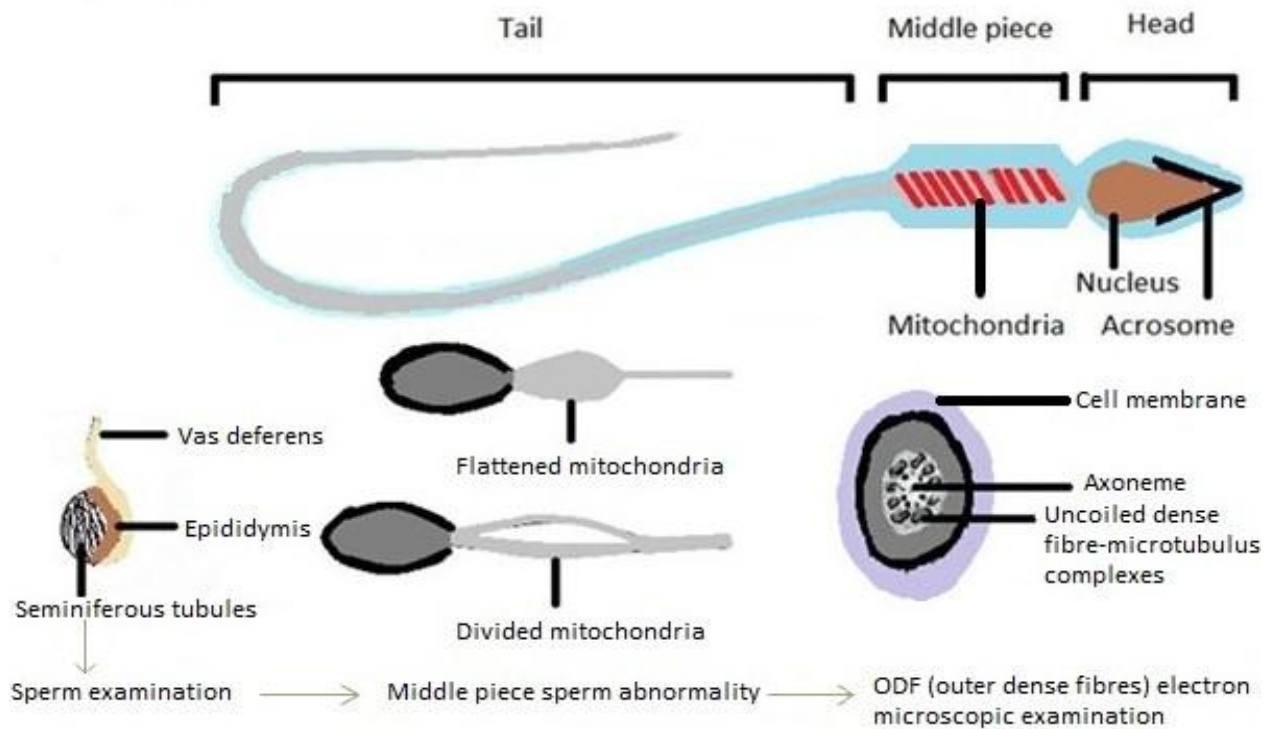


- nanoparticles administration," *Vet World*, vol. 6, pp. 534-537, 2013. Available at: <https://doi.org/10.5455/vetworld.2013.534-537>.
- [33] A. A. Hafiez, Z. H. M. El-Kirdassy, N. M. El-Malkh, and E. M. I. El-Zayat, "Role of zinc in regulating the testicular function part 3. Histopathological changes induced by dietary zinc deficiency in testes of male albino rats," *Food / Nahrung*, vol. 34, pp. 65-73, 1990. Available at: <https://doi.org/10.1002/food.19900340114>.
- [34] D. K. Schampelaere, M. Canli, V. Van Lierde, I. Forrez, F. Vanhaecke, and C. Janssen, "Reproductive toxicity of dietary zinc to *Daphnia magna*," *Aquatic Toxicology*, vol. 70, pp. 233-244, 2004. Available at: <https://doi.org/10.1016/j.aquatox.2004.09.008>.
- [35] A. Sharma, B. Patni, D. Shankhdhar, and S. C. Shankhdhar, "Zinc—an indispensable micronutrient," *Physiology and Molecular Biology of Plants*, vol. 19, pp. 11-20, 2013. Available at: <https://doi.org/10.1007/s12298-012-0139-1>.
- [36] E. Gilabert, E. Ruiz, C. Osorio, and E. Ortega, "Effect of dietary zinc deficiency on reproductive function in male rats: Biochemical and morphometric parameters," *The Journal of Nutritional Biochemistry*, vol. 7, pp. 403-407, 1996. Available at: [https://doi.org/10.1016/s0955-2863\(96\)00063-0](https://doi.org/10.1016/s0955-2863(96)00063-0).
- [37] B. Baccetti, V. Pallini, and A. G. Burrini, "The accessory fibers of the sperm tail," *Journal of Ultrastructure Research*, vol. 54, pp. 261-275, 1976. Available at: [https://doi.org/10.1016/s0022-5320\(76\)80118-9](https://doi.org/10.1016/s0022-5320(76)80118-9).
- [38] A. Ashrafzadeh, S. A. Karsani, and S. Nathan, "Mammalian sperm fertility related proteins," *International Journal of Medical Sciences*, vol. 10, pp. 1649-1657, 2013. Available at: <https://doi.org/10.7150/ijms.6395>.
- [39] S. Murarka, V. Mishra, and P. Joshi, "Role of zinc in reproductive biology - an overview," *Molecular Medicine*, vol. 2, pp. 1-8, 2015.
- [40] H. A. Vergnes, M. K. Courdouhji, J. F. Guelfi, J. G. Grozdea, and M. Lamand, "Effect of zinc deficiency in lambs on plasma and neutrophil alkaline phosphatase," *Small Ruminant Research*, vol. 3, pp. 167-177, 1990. Available at: [https://doi.org/10.1016/0921-4488\(90\)90090-s](https://doi.org/10.1016/0921-4488(90)90090-s).
- [41] B. T. Akingbemi, "Estrogen regulation of testicular function," *Reproductive Biology and Endocrinology*, vol. 3, pp. 1-13, 2005.
- [42] M. K. Sankako, P. C. Garcia, R. C. Piffer, B. Dallaqua, D. C. Damasceno, and O. C. Pereira, "Possible mechanism by which zinc protects the testicular function of rats exposed to cigarette smoke," *Pharmacological Reports*, vol. 64, pp. 1537-1546, 2012. Available at: [https://doi.org/10.1016/s1734-1140\(12\)70951-9](https://doi.org/10.1016/s1734-1140(12)70951-9).



**Fig-1.** FSH and LH plays a key role in sperm production and in the process of spermatogenesis. But, various studies reported that gonadotropin-inhibitory hormone (GnIH) negatively affects the hypothalamic-pituitary gonadal axis (HPG axis) and disturb the testosterone level and ultimately hinder the spermatogenesis.

Source: Shahraki, et al. [1]



**Fig-2.** Sperm morphology plays an important role in ova fertilization. Healthy sperm consists of normal head, middle and tail piece. By electron microscopic examination of rat sperm, it is reported that Zn deficiency affects the middle piece (ODF) of sperm and produce the sperm structural abnormalities. As consequences it may lead to infertility.

Source: Yattoo, et al. [2]

*Views and opinions expressed in this article are the views and opinions of the author(s), Animal Review shall not be responsible or answerable for any loss, damage or liability etc. caused in relation to/arising out of the use of the content.*