

Cancers Review

2014 Vol.1, No.1, pp.5-15

ISSN(e): 2408-9273

ISSN(p): 2409-2053

DOI: 10.18488/journal.95/2014.1.1/95.1.5.15

© 2014 Conscientia Beam. All Rights Reserved



ULTRASOUND GUIDED AXILLARY NODE SAMPLING IN PATIENTS OF CARCINOMA BREAST WITH CLINICALLY NEGATIVE AXILLA: A PILOT STUDY

Navneet Kaur¹ --- Akhil Garg² --- Anupama Tandon³ --- Usha Rani Singh⁴

¹Department of Surgery, University College of medical Sciences & GTB Hospital, University of Delhi, Delhi, India

²Department of Surgery, UCMS & GTB Hospital, University of Delhi, Delhi, India

³Department of radiology, UCMS & GTB Hospital, University of Delhi, Delhi, India

⁴Department of Pathology, UCMS & GTB Hospital, University of Delhi, Delhi, India

ABSTRACT

Background: The current recommendation for evaluation of axilla in patients with early breast cancers is Sentinel Lymph Node Dissection. Axillary node sampling (ANS) has been validated as an alternative, but its reliance on palpation for localization of axillary nodes limits its precision. Pre-operative ultrasound guided localization can be combined with ANS to overcome this limitation. We conducted this study to find the accuracy of Ultrasound Guided Axillary Node Sampling (UGANS) in predicting the status of the axilla in patients with breast cancer. *Methods:* Forty patients of carcinoma breast with clinically negative axilla underwent pre-operative ultrasonography to identify axillary nodes with suspicion of metastatic involvement. Identified nodes were marked on the skin by a permanent marker and depth from the surface was recorded. The patients underwent mastectomy/breast conservation surgery with axillary dissection. The pre-operatively marked nodes were first dissected out under guidance of the skin markings and subsequently complete axillary lymph node dissection (ALND) was performed. Based on histopathological correlation, accuracy of UGANS was calculated taking ALND as the gold standard. *Results:* Thirty eight (95%) patients had successful marking of axillary nodes by ultrasonography (USG) (Mean 3.89 nodes). Thirty four (85%) patients had successful sampling of marked nodes (Mean-3.76 nodes). There was a higher rate of sampling failure in patients with negative axilla (3/17, 17.6%) than those with axillary metastasis (1/21, 4.76%). Patients in whom marked nodes could not be localized were mostly young (mean age 39 years), had significantly higher body mass index (BMI) score (mean 31.38 Kg/m² versus 24.84 kg/m², p = 0.006), and smaller size of marked nodes (mean 0.99 cm in failure group versus 1.03 cm in successful group). The nodes sampled with USG guidance reflected the status of axilla with accuracy of 100%. *Conclusion:* The present study establishes the feasibility and accuracy of UGANS as a potential cost effective axillary staging modality in low resource settings. However, more studies with a larger sample size are required to validate these initial results.

Keywords: Axillary sampling, Breast cancer, Ultrasound, Clinically negative axilla.

1. INTRODUCTION

In early breast cancer with clinically negative axilla, sentinel lymph node biopsy (SLNB) has emerged as a reliable technique for evaluating the status of axillary metastasis while decreasing the morbidity of axillary dissection [1]. However the technique is expensive and requires access to radio-isotopes and frozen-section histological analysis facilities which may not be possible in smaller institutions. If the sentinel node is positive, then a further operation may be required if intra-operative lymph node assessment is either not available, or comes positive on hematoxylin and eosin (H & E) staining. Besides, even though SNB concept suggests removal of the single first node draining the tumor, many reports have described excision of multiple lymph nodes (mean number 1.4-3.1) [2, 3].

Axillary node sampling (ANS) in the form of four node or five node sampling has been reported as a useful method to evaluate axilla for a long time. It involves surgical exposure and mobilization of axillary tail of breast between serratus anterior and lateral border of latissimus dorsi muscle and a careful search by inspection and palpation for the suspicious nodes till 4-5 nodes are identified. Many studies on four node or five node sampling have reported accuracy rates up to 96-98% [4, 5]. ANS is a cheap and easy technique and suited for low resource settings across the world. However the technique lacks standardization and its reliance on palpation of nodes limits its precision.

Evaluation by preoperative ultrasound (USG) in patients with early breast cancer has been found to be a very useful tool for staging axilla. If USG detects axillary metastasis, the SLNB can be omitted and axillary lymph node dissection (ALND) can be performed directly. High rates of diagnostic accuracy have been reported in the assessment of axilla by USG [6]. USG guided fine needle aspiration cytology (FNAC) has been suggested to further improve the accuracy of USG. Axillary ultrasound guided -FNAC has been reported to have a high specificity (96-100%) but low sensitivity (28% -54%) in detecting metastasis [7, 8]. Hence a positive biopsy specimen decreases the need for a sentinel node biopsy. However a negative result does not replace the need for SLNB / ANS for staging of axilla.

We hypothesized that combining the techniques of USG and ANS, a higher accuracy in the assessment of axilla should be achieved. Hence we planned this study to combine ANS with preoperative assessment of axilla with USG, and choose those nodes for sampling which were found to have features suggestive of metastatic involvement with the expectation that ultrasound guided axillary node sampling (UGANS) will increase the diagnostic accuracy of ANS

2. MATERIAL & METHODS

This prospective study was conducted on 40 consecutive patients with biopsy proven breast cancer with clinically negative axilla. All of these patients were planned to undergo surgery (breast conservation or modified radical mastectomy with axillary clearance). Approval by the institutional ethics committee was obtained and patients were entered prospectively into the study protocol after signing an informed consent. The patients underwent a detailed clinical examination and baseline haematological investigations including full blood count, blood urea, blood sugar and complete liver function tests. They were subjected to other investigations for staging and metastatic work up as indicated, including mammography, chest X-ray, abdomen USG, bone scan, CT scan etc.

All these patients were subjected to preoperative USG of the axilla to determine the presence of nodes which were sonographically suspicious of malignancy. The descriptors which were considered suspicious were A. size more than 10mm; B. absence of fatty hilum; C. hypoechoic internal echo; D. circular shape; E. sharply demarcated border compared with surrounding fatty tissue; F. asymmetric cortical thickening or eccentric lobulations of hypoechoic cortical rim [9, 10]. Findings were noted with regard to the level and number of suspicious nodes. The details of descriptors characterizing findings of suspicious nodes in each case were also noted. These nodes were marked on the skin with an indelible marker and depth from the skin surface was also noted. (Fig 1) At the time of surgery, after mobilization of the axillary tail of breast, these nodes were taken out from the axillary fat pad separately with their localization being guided by skin marking. (Fig 2) In obese patients with abundant axillary fat it was difficult initially to locate the node, but with experience we overcame the problem. After sampling of these suspicious nodes, axillary dissection was completed along with surgery for the primary lesion.

Lymph nodes dissected out of the axilla were subjected to histopathological examination for metastatic disease. Based on the correlation of USG and histopathologic (HPE) findings, diagnostic accuracy of USG was calculated.

We also divided marked nodes into benign, suspicious, and involved categories based on their sonographic features [10]. Nodes with uniform widening of the cortex and echogenic hilum positioned symmetrically in the centre of the node were considered benign. (Fig 3) Nodes which had round shape with loss of fatty hilum and hypoechoic internal architecture were taken as involved nodes. (Fig 4) Nodes which showed enlargement with sharp demarcated margins, asymmetric cortical thickening or cortical lobulations were considered suspicious of harboring metastasis. (Fig 5) Correlation of the three categories as defined on axillary USG was done with their histopathological report to calculate the accuracy of USG in predicting axillary metastasis

3. RESULTS

Forty patients with biopsy proven breast cancer with clinically negative axilla were included in the study. The youngest patient in this study was 27 years old and the oldest was 64 years old. Most of the patients (42%) were in the age group of 35-45 years. All patients were female. Upper outer quadrant was the most common location (72.4%) for primary lesion in the breast. Regarding the tumor size, 10% had T1 tumor, 66.4% had T2 tumor and 23.6 % had T3 tumor. Around 77 % of patients with lump size exceeding 5 cm were detected to have axillary metastasis on biopsy as compared to 33% in the group with lump size < 2cm. In 21 patients metastasis were present in axillary nodes (52.5%), while 19 patients had negative axilla (47.5%). Out of these 21 patients, 19 had metastasis in more than 4 nodes, while 2 patients had metastasis in 1-3 nodes.

3.1. Performance of USG Guided Axillary Node Marking

Lymph nodes were demonstrated in 38 patients (95%) with preoperative ultrasonography of the axilla. In 2 patients no nodes could be identified. In these 2 patients HPE was negative for axillary metastasis. In 38 patients USG guided marking of the lymph nodes was done and a total of 148 nodes were marked (average 3.89 nodes). Although most nodes were marked at level I (140 nodes), in 5 patients 8 nodes were marked at level II.

3.2. Performance of UGANS Sampling

Performance of ultrasound guided node sampling is shown in Table 1. At the time of axillary dissection , sampling of marked nodes was successful in 34 patients (89.5%). In these 34 patients, out of marked 138 nodes, 128 nodes were sampled (average 3.76 sampled node/ patient). In 4 patients we were not able to sample the marked nodes. On analysis of the characteristics of these 4 patients in whom marked nodes could not be localized, the factors which were found to have significant association were young age (mean age 39 years), higher BMI score (mean 31.38 Kg/m² versus 24.84 kg/m² , p = 0.006), and smaller size of marked nodes (mean 0.99 cm in failure group versus 1.03 cm in successful group). Also there was a higher rate of sampling failure in patients with negative axilla (3/17, 17.6%) than those with axillary metastasis (1/21, 4.76%).

3.3. Diagnostic Accuracy of UGANS

Table 2 depicts correlation of histopathology of ultrasound guided sampled nodes with status on ALND. Overall performance of USG (including 2 patients where nodes could not be marked and also those 4 where sampling could not be achieved) was 85%. Out of 34 patients with successful sampling, 20 had axillary metastasis. In all these patients status of the successfully

sampled nodes with USG guidance had 100% correlation with histopathological status of the axilla thus proving its worth as a guiding tool for sampling. Out of the 138 marked nodes in these 34 patients, 128 could be sampled. In 78 nodes metastasis were present while 50 were free. On further analysis of the data we found that in 2 patients metastasis were present only in the nodes which were sampled and the number of involved nodes were 2 for each patient.

3.4. Accuracy of Axillary USG in Predicting Nodal Metastasis

In 38 patients in whom USG guided marking of lymph nodes was done, USG was able to pick up nodal metastasis with sensitivity of 95.2%, specificity of 64.7% , positive predictive value 76.92%, negative predictive value 91.6% and diagnostic accuracy of 81.5%. All 9 patients with nodes marked as involved, had metastasis on HPE (9/9, 100%). In 17 patients with nodes marked suspicious, 11 had metastasis (11/17, 64.7%). In 12 patients with nodes marked benign 1 had metastasis, rest 11 were true negative (11/12, 91.6%). (Table 3)

4. DISCUSSION

Metastatic involvement of axillary lymph node is the single most important prognostic factor in breast cancer. The presence of axillary involvement in breast cancer determines patient's survival and staging of the disease and plays an important part in local control. Until recently ALND dissection was considered as the reference method for detecting lymph node involvement. However the rate of axillary lymph node metastasis is very low in patients diagnosed at an early stage [11, 12]. Hence studies in the last decade discourage the use of ALND because of significant associated morbidities such as lymphedema, paresthesias, infection, decreased range of movement of shoulder etc. To avoid these unnecessary morbidities, the concept of SLNB has gained increasing acceptance. Studies have proved that the drainage of breast lymphatics is in an orderly manner through initial node(s) – the sentinel lymph node (SLN) and almost 100% of breast cancers drain to axilla irrespective of the primary tumor's location. [13] Studies have proved that SLND alone is sufficient for management of axilla in early cancers if SLN is negative [14, 15]. However high setup and operating costs and complex techniques have limited the widespread application of this technique. It would be valuable if sentinel node biopsy could be replaced by easier methods.

ANS has been reported to be an effective method for managing patients of early cancer with clinically negative axilla and is widely practiced in England [4]. However its acceptance has been low compared to SLNB. Possibly one reason is that the method of picking up nodes for sampling is empirical. Another is the amount of dissection required to mobilize axillary tail to palpate the nodes is much more than would be required if SLNB is being done. Another problem area could

be patients with high axillary fat content which may hamper the palpation of nodes along the axillary tail of the breast.

Guided sampling by combining ANS with blue dye method of sentinel node biopsy has been studied by various workers with the expectation to improve results. Higher rates of detection of axillary node metastasis to the tune of 3-13% have been reported on sampling of additional nodes after sentinel node detection [16-18]. A possible explanation for this finding is the failure of blue dye to reach the sentinel node due to blockage of the lymphatic channels by the cancer cells.

Sampling of nodes under ultrasound guidance effectively addresses the issue of picking up those nodes which are most likely metastatic. ANS relies on the theory that involved axillary nodes are the ones most likely to be palpable intra-operatively. The potential pitfalls are that nodes that are palpable may be enlarged due to benign reactive hyperplasia following core cut biopsy or excision biopsy due to activation of reticuloendothelial system. Besides lymph node enlargement is also seen in response to fibrocystic changes and infections. Second potential pitfall is that metastatic nodes may not always be enlarged. In one large series, an average diameter of 6.5 was determined for uninvolved lymph nodes and 9.7 mm for metastatic nodes with a range from 1.8 to 40.6 mm. Thus while larger nodes tend to correlate with metastasis, even small lymph nodes a few mm in diameter may contain metastasis [19]. Another possible advantage of USANS over standard ANS could be sampling of nodes in patients with high axillary fat content. While we found higher rate of sampling failure in patients with high BMI in the early part of our study, later on by digging deep into the area under USG guided skin marking, we were able to retrieve nodes more easily than would have been the case if there was no marking to locate the suspicious nodes.

UGANS also limits the amount of axillary dissection required to sample the suspicious nodes. A conventional ANS or even blue dye guided sampling would require far more mobilization of tissue along the axillary tail of breast. Extent of axillary dissection has been hypothesized to be responsible for intermediate and long term morbidities such as lymphedema, paresthesia and decreased range of shoulder movement. In order to minimize dissection, attempts have been made to identify axillary zones which are most likely to harbour sentinel nodes. Clough, et al. [20] described a new anatomical classification of axilla where zones A and B alongside the lateral thoracic vein and second intercostobrachial nerve were found to harbor sentinel node in 98.2% of cases and they suggested that with this information unnecessary lateral dissections should be avoided.

However UGANS has its own set of issues to be addressed. First pitfall is the inability to mark nodes which happened in 5% of our patients. However none of these patients had axillary metastasis. Reason for not finding nodes in these patients could be that the cortices of normal

nodes are isoechoic with the axillary fat and unless the nodes can be identified by its more echogenic hilar fat, axillary nodes may not be conspicuous with ultrasound. Thus if ultrasonologist do not find any nodes, metastasis are very unlikely and node sampling can be done by method of palpation of nodes along axillary tail intra-operatively. Second problem is not being able to sample nodes which have been marked by USG. This can partly be overcome with experience, especially in obese patients. But probably the best solution would be to perform intraoperative ultrasound with a high frequency probe to localize involved nodes at the time of axillary dissection.

5. CONCLUSION

UGANS sampling has high rate of diagnostic accuracy and could be a valuable tool for evaluation of axillary metastasis in early breast cancer in low resource settings. However it may not be feasible to do it in all cases due to failure to identify nodes or failure to sample marked nodes. When nodes are not identified at all, then chances of metastasis are minimal. Higher experience with the technique may decrease the rate of failure. Availability of Intra-operative USG for assessment of lymph nodes may prove to be a helpful tool for sampling of suspicious nodes.

REFERENCES

- [1] D. Zarebczan and H. Neuman, "Management of axilla," *Surg Clin N Am.*, vol. 93, pp. 429-444, 2013.
- [2] U. Veronesi, G. Paganelli, V. Galimberti, G. Viale, S. Zurrida, and M. Bednoi, "Sentinel node biopsy to avoid axillary dissection in breast cancer with clinically negative nodes," *Lancet*, vol. 349, pp. 1864-1867, 1997.
- [3] D. J. Winchester, S. F. Sener, D. P. Winchester, G. Perlman, R. A. Goldschmidt, and G. Motykie, "Sentinel lymphadenectomy for breast cancer: Experience with 180 consecutive patients: Efficacy of filtered technetium 99m sulphur colloid with overnight migration time," *J Am Coll Surg*, vol. 188, pp. 597-603, 1999.
- [4] R. D. Macmillan, D. Barbera, D. J. Hadjiminias, R. S. Rampaul, A. H. Lee, and S. E. Pinder, "Sentinel node biopsy for breast cancer may have little to offer four-node samplers: Results of a prospective comparison study," *EJC.*, vol. 37, pp. 1076-80, 2001.
- [5] K. Tanaka, D. Yamamoto, S. Kanematsu, H. Okugawa, and Y. Kamiyama, "A four node sampling trial on breast cancer patients," *Breast*, vol. 15, pp. 203-209, 2006.
- [6] Y. S. Rajesh, S. Ellenbogen, and B. Banerjee, "Preoperative axillary ultrasound scan: Its accuracy in assessing the axillary nodal status in carcinoma breast," *Breast*, vol. 11, pp. 49-52, 2002.
- [7] B. P. Baruah, A. Goyal, P. Young, A. G. Douglas-Jones, and R. E. Mansel, "Axillary node staging by ultrasonography and fine needle aspiration cytology in patients with breast cancer," *Br J Surg*, vol. 97, pp. 680-683, 2010.

- [8] M. S. Cowher, K. M. Erb, W. Poller, and T. B. Julian, "Correlation of the use of axillary ultrasound and lymph node needle biopsy with surgical node pathology in patients with invasive breast cancer," *Am J Surg*, vol. 196, pp. 756-759, 2008.
- [9] M. B. Popli, M. Sahoo, N. Mehrotra, M. Choudhry, A. Kumar, and O. P. Pathania, "Preoperative ultrasound –guided fine needle aspiration cytology for axillary staging in breast carcinoma," *Australas Radiol*, vol. 50, pp. 122-126, 2006.
- [10] N. Kaur, P. Sharma, A. Garg, and A. Tandon, "Accuracy of individual descriptors and grading of nodal involvement by axillary ultrasound in patients of breast cancer," *International Journal of Breast Cancer*.
- [11] C. Lanng, J. Hoffmann, and H. Galatius, "Assessment of clinical palpation of the axilla as a criteria for performing the sentinel node procedure in breast cancer," *Eur J Surg Oncol*, vol. 33, pp. 281-284, 2007.
- [12] B. A. Minecny, T. Bammer, E. J. Atkinson, and E. A. Perez, "Role of axillary node dissection in patients with T1a and T1b breast cancer: Mayo clinic experience," *Arch Surg*, vol. 136, pp. 779-82, 2001
- [13] S. Shivers, C. Cox, and G. Leight, "Final results of the department of defense multicenter breast lymphatic mapping trial," *Ann Surg Oncol*, vol. 9, pp. 248-255, 2002.
- [14] L. Bergkvist and J. Frissell, "Multicentre validation study of sentinel node biopsy for staging in breast cancer," *Br J Surg*, vol. 92, pp. 1221-1224, 2005.
- [15] U. Veronesi, G. Paganelli, G. Viale, A. Luini, S. Zurrada, and V. Galimberti, "Sentinel lymph node biopsy as a staging procedure in breast cancer: Update of a randomized controlled study," *Lancet Oncol*, vol. 7, pp. 983-90, 2006.
- [16] F. J. Hoar and P. S. Stonelake, "A prospective study of the value of axillary node sampling in addition to sentinel lymph node biopsy in patients with breast cancer," *Eur J Surg Oncol*, vol. 29, pp. 526-31, 2003.
- [17] U. Chetty, P. K. Chin, P. H. Soon, W. Jack, and J. S. Thomas, "Combination blue dye sentinel lymph node biopsy and axillary node sampling: The edinburgh experience," *EJSO*, vol. 34, pp. 13-16, 2008.
- [18] K. Narui, T. Ishikawa, A. Kito, D. Shimizu, T. Chishima, and N. Momiyama, "Observational study of blue dye-assisted four-node sampling for axillary staging in early breast cancer," *EJSO*, vol. 36, pp. 731-736, 2010.
- [19] H. Madjar and E. B. Mendelson, *The practice of breast ultrasound*. New York: Thieme Publishing Group Stuttgart, 2008
- [20] K. B. Clough, R. Nasr, C. Nos, M. Vieira, C. Ingmnault, and B. Poulet, "New anatomical classification of the axilla with implications for sentinel node biopsy," *Br J Surg*, vol. 97, pp. 659-1665, 2010.

Table-1. Performance of USG guided node sampling

| | No. Of patients | Percentage | No. Of nodes marked | No. Of nodes found |
|-------------------------------------|-----------------|------------|---------------------|--------------------|
| Patients with successful sampling | 34 | 85 | 138 | 128 |
| Patients with unsuccessful sampling | 4 | 10 | 10 | 0 |
| Patients with unsuccessful marking | 2 | 5 | - | 0 |
| Total | 40 | 100 | 148 | 128 |

Table-2. Accuracy of USG guided node sampling in predicting axillary nodal status as found on ALND

| USG guided sampled nodes | Axillary metastases on ALND | |
|--|-----------------------------|----------|
| | Positive | Negative |
| Metastases positive (n=20) in sampled nodes on HPE | 20 | 0 |
| Metastases negative (n=14) in sampled nodes on HPE | 0 | 14 |
| Not found (n=4) | 1 | 3 |
| Not marked (n=2) | 0 | 2 |
| Total | 21 | 19 |

Table-3. Correlation of USG categories with histopathology reports

| USG Marked nodes | Axillary metastases on biopsy | |
|------------------------------|-------------------------------|------------------|
| | Positive | Percent Accuracy |
| Benign (n=12) | 1 | 91.6 |
| Suspicious (n=17) | 11 | 64.7 |
| Involved by metastatic (n=9) | 9 | 100 |

LEGENDS

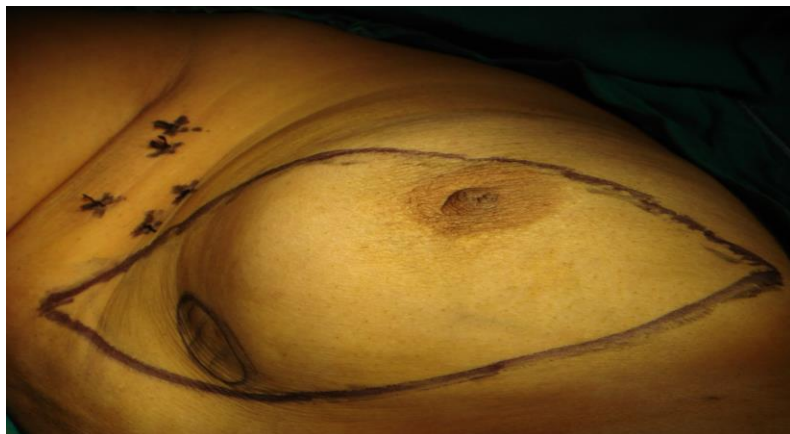

Figure-1. USG guided skin marking of suspicious nodes

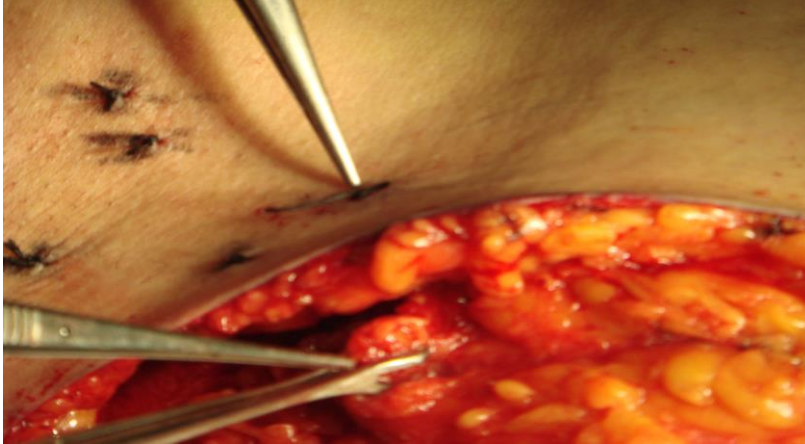


Figure-2. Sampling of suspicious nodes marked with USG guidance

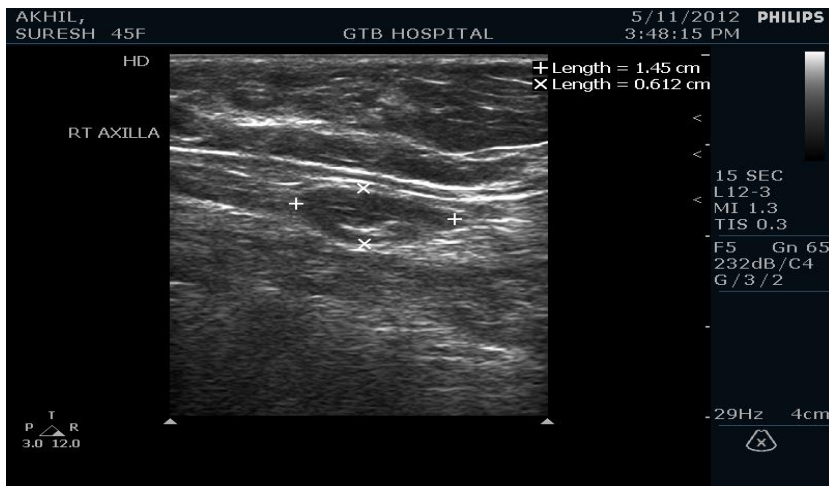


Figure-3. Benign node : oval shape, preserved central hilum

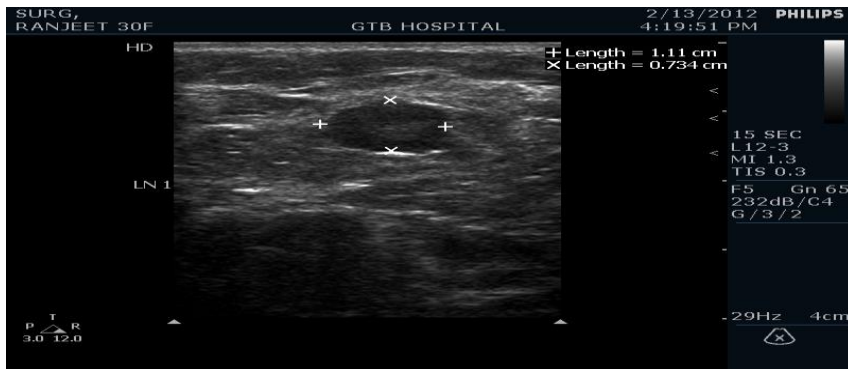


Figure-4. Suspicious node: sharply demarcated borders, asymmetric cortical thickening, displaced hilum

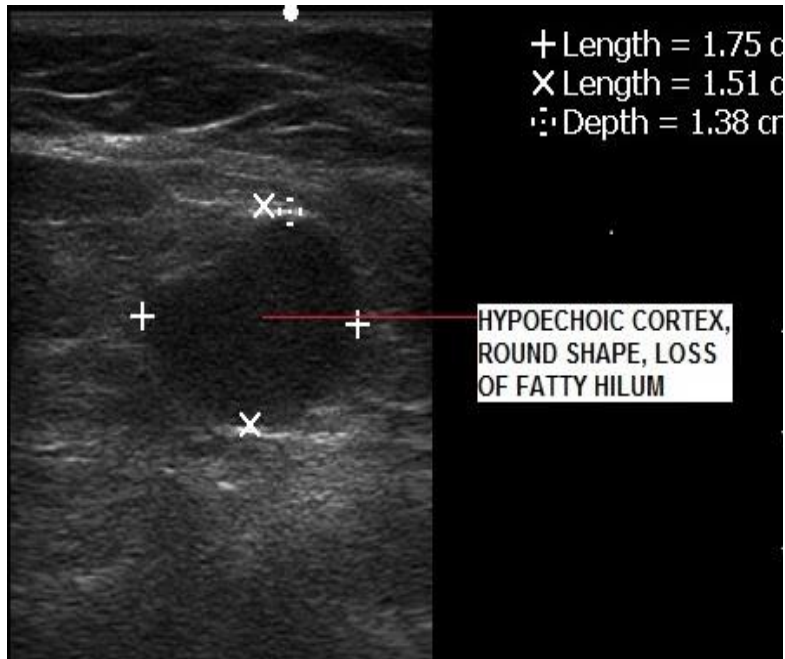


Figure-5.Metastatic node: round shape, loss of fatty hilum, hypoechoic internal echo

Views and opinions expressed in this article are the views and opinions of the author(s), Cancers Review shall not be responsible or answerable for any loss, damage or liability etc. caused in relation to/arising out of the use of the content.