



## CHONDROSARCOMA OF THE UPPER EXTREMITY OF THE HUMERUS: A CASE REPORT

Abdelilah Mouhsine<sup>1†</sup> --- Hicham Sallahi<sup>2</sup> --- Ahmed Belkouch<sup>3</sup> --- El Mehdi Atmane<sup>4</sup> --- Redouane Rokhssi<sup>5</sup> --- Youssef Berrada<sup>6</sup> --- Khalid Koulali<sup>7</sup> --- Lahcen Belyamani<sup>8</sup> --- Abdelghani ElFikri<sup>9</sup> --- Mbarek Mahfoudi<sup>10</sup>

<sup>1, 4, 5, 6, 9, 10</sup> Department of Radiology HMA, Marrakech, Morocco

<sup>2, 7</sup> Department of traumatology HMA, Marrakech, Morocco

<sup>3, 8</sup> Emergency Department, Military Hospital of Instruction Mohamed V, Rabat, Morocco

### ABSTRACT

*Chondrosarcomas are frequent bone tumors, just after osteosarcomas, they represent 11 to 22% of all bone tumors. Proximal humerus localization occurs in about 9% of cases, the clinical picture is variable, imagery helps to establish the diagnosis, to give an exact lesion assessment and to guide therapeutic attitude and post treatment control. Confirmation is set by histology. We highlight through this case presentation clinical and radiological aspects of these tumors.*

### 1. INTRODUCTION

Chondrosarcoma is the most common primary malignant bone tumor after osteosarcoma [1]. The entire skeleton can be reached; localization in the proximal humerus is rare (9%) (2).

The onset is often insidious reflecting the slow growth of these tumors that reveal usually by a painless mass. Using the semiological characteristics of the tumor, Imagery helps to establish the diagnosis, gives an exact lesion assessment, guides therapeutic attitude and post treatment control. Confirmation is set by histology.

The authors highlight through this case the specific clinical and radiological characteristics of a relatively rare localization of this tumor.

#### 1.1. Case Presentation

A 48 years old male patient presented with swelling of the left shoulder lasting for six months, having recently increased in size and became painful. Inspection revealed a vicious

attitude of the upper limb, with anatomical landmarks deformation and without inflammatory manifestations of the skin next to the tumor. Palpation found a hard mass deeply adhering, without vasculo nervous abnormalities below to it.

Standard antero-posterior and lateral radiographs (Figures 1a, b) showed at the left humeral head the presence of a heterogeneous lesion osteo-condensating, bluntly rounded seat of some calcifications. The CT scan showed a voluminous cartilaginous lesion, osteo-condensating heterogeneous, seat of some micro calcifications. This lesion is centered on the greater tuberosity of the humerus with posterior development, breaking the cortical and the soft tissue next to it without any signs of invasion of these structures (Figure 2). This radiographic appearance evokes a priori a malignant tumor with cartilaginous matrix (chondrosarcoma). Considering the localization, the cartilaginous matrix (calcifications), and the aggressivity of this tumor (rupture of the cortical, peri osseous reaction, soft tissues invaded) other histological types can be suspected: osteosarcoma, metastases, degeneration of an exostosis. A biopsy was performed and histological study concluded to chondrosarcoma.

## 2. DISCUSSION

Chondrosarcoma is the most common primary malignant bone tumor after osteosarcoma; it represents 11 to 22% of all bones tumors according to Dahlin [1]. There is a discreet male predominance [1, 2]. The age of onset of these tumors is mostly between 40 and 70 years old [3, 4] as for our patient; only 4% of patients are under 20 years and 40 to 47% are over 40 years old [1, 2]. The discovery of a chondrosarcoma before the age of 20 years suggests the diagnosis of chondroblastic osteosarcoma. [5] Approximately 10% of chondrosarcomas occur on pre-existing bone lesions.

The symptoms are often discrete, with insidious onset reflecting the slow growth of these tumors. The mean duration of symptoms is 1 to 2 years; it is shorter when the tumor is located in the members or in the pelvis [6, 7]. Presenting symptoms are most often, pain or swelling discovered by the patient, our patient discovered by himself the mass but did not reveal it until it became painful. Pathological fractures are rare (3%); they occur most often in tumors with high histological grade [3].

The entire skeleton can be reached, but the most commonly affected sites are the pelvis (24 to 38%) and proximal femur (16 to 27%) [2-4, 8]. Other sites can be the ribs (8%), proximal humerus (9%), distal femur (6%), the scapula and the proximal tibia [3, 4]. Spinal localizations are rare (1-7%) [3, 4]. Chondrosarcoma of the bones of the hand and feet represents less than 3% of all locations [9, 10]. They usually occur on an isolated chondroma or within the scope of Ollier disease [11]. The central chondrosarcomas are located preferentially in the humerus and femur, and peripheral ones on the flat bones (pelvis, scapula, ribs) [5].

The diagnosis is often strongly suspected on standard radiographs. CT scan allows visualizing the cartilage matrix of the lesion, characterized by the presence of micro calcifications, and a finer appreciation of bone resorption and eventual rupture of the cortex. The magnetic

resonance imaging (MRI) is especially relevant to radiolucent tumors; it is useful for the loco regional staging and to find *skip metastases*.

The differential diagnosis can be done with osteosarcoma and osseous metastases. The diagnosis is only confirmed by histology.

The local recurrence rate varies according to the series: it is 6% for Pritchard, et al. [12], 11% according to Evans, et al. [6], 24% for Lee, et al. [3], 28% for Campanacci [2] and 33% for Marcove, et al. [13]. There are special forms for chondrosarcoma: secondary chondrosarcoma of Chondromas or osteogenic exostosis, the periosteal chondrosarcomas the clear cell chondrosarcomas, mesenchymal chondrosarcoma and dedifferentiated chondrosarcoma with poor prognosis.

The only effective treatment is wide surgical resection, because it is a radio and chemo-resistant tumor, the removal must meet the usual rules of oncologic surgery which is becoming increasingly conservative; it imposes a reconstruction that uses the techniques of osteosynthesis, the massive prosthesis, and self-allografts [14]. However, amputation may be the last solution in case of large tumors invading vessels and nerves, infection on biopsy, or recurrence after multiple interventions. [14].

### 3. CONCLUSION

Chondrosarcomas are frequent bone tumors, just after osteosarcomas, they represent 11 to 22% of all bone tumors. Proximal humerus localization occurs in about 9% of cases, the clinical picture is variable, imagery helps to establish the diagnosis, to give an exact lesion assessment and to guide therapeutic attitudes and post treatment control. Confirmation is set by histology.

### REFERENCES

- [1] D. Dahlin, *Bone tumors: General aspect and data on 6 221 cases*. Springfield: CC Thomas, 1978.
- [2] M. Campanacci, *Bone and soft tissue tumors*. New York: Springer-Verlag, 1986.
- [3] F. Lee, H. Mankin, G. Fondren, M. Gebhardt, D. Springfield, and A. Rosenberg, "Chondrosarcoma of bone. An assessment of outcome," *J Bone Joint Surg Am.*, vol. 81, pp. 326-338, 1999.
- [4] E. Ucla, B. Tomeno, and M. Forest, "Facteurs du pronostic tumoral dans les chondrosarcomes de l'appareil locomoteur," *Rev Chir Orthop.*, vol. 77, pp. 301-311, 1991.
- [5] M. Forest, *Orthopedic surgical pathology: Diagnosis of tumors and pseudotumoral lesions of bone and joint*. In : Forest M, Tomeno B, Vanel D Eds. Edinburgh: Churchill Livingstone, 1998.
- [6] H. Evans, A. Ayala, and M. Romsdhal, "Prognostic factors in chondrosarcoma of bone. Clinicopathologic analysis with emphasis on histologic grading," *Cancer*, vol. 40, pp. 818-831, 1977.
- [7] D. Springfield, M. Gebhardt, and M. McGuire, "Chondrosarcoma: A review," *J Bone Joint Surg Am.*, vol. 78, pp. 141-149, 1996.
- [8] K. Unni, D. Dahlin, J. Beabout, and F. Sim, "Chondrosarcoma: Clear-cell variant. A report of sixteen cases," *J Bone Joint Surg Am.*, vol. 58, pp. 676-683, 1976.

- [9] J. Bovée, R. Van Der Heul, A. Taminiau, and P. Hogendoorn, "Chondrosarcoma of the phalanx: A locally aggressive lesion with minimal metastatic potential: A report of 35 cases and a review of the literature [See Comments]," *Cancer*, vol. 86, pp. 1724-1732, 1999.
- [10] T. Cawte, G. Steiner, J. Beltran, and H. Dorfman, "Chondrosarcoma of the short tubular bones of the hands and feet," *Skeletal Radiol.*, vol. 27, pp. 625-632, 1998.
- [11] R. Gaulke and P. Preisser, "Secondary chondrosarcoma of the hand. Case report and review of the literature," *Handchir Mikrochir Plast Chir.*, vol. 29, pp. 251-255, 1997.
- [12] D. Pritchard, R. Lunke, W. Taylor, D. Dahlin, and B. Medley, "Chondrosarcoma: A clinicopathologic and statistic analysis," *Cancer*, vol. 45, pp. 149-157, 1980.
- [13] R. Marcove, V. Mike, R. Hutter, A. Huvos, H. Shoji, and T. Miller, "Chondrosarcoma of the pelvis and upper end of the femur," *J Bone Joint Surg Am.*, vol. 54, pp. 561-572, 1972.
- [14] Encyclopédie Médico-Chirurgicale, "Appareil locomoteur," *Chondrosarcomes Intraosseux*, vol. 14-716, pp. 10-12.

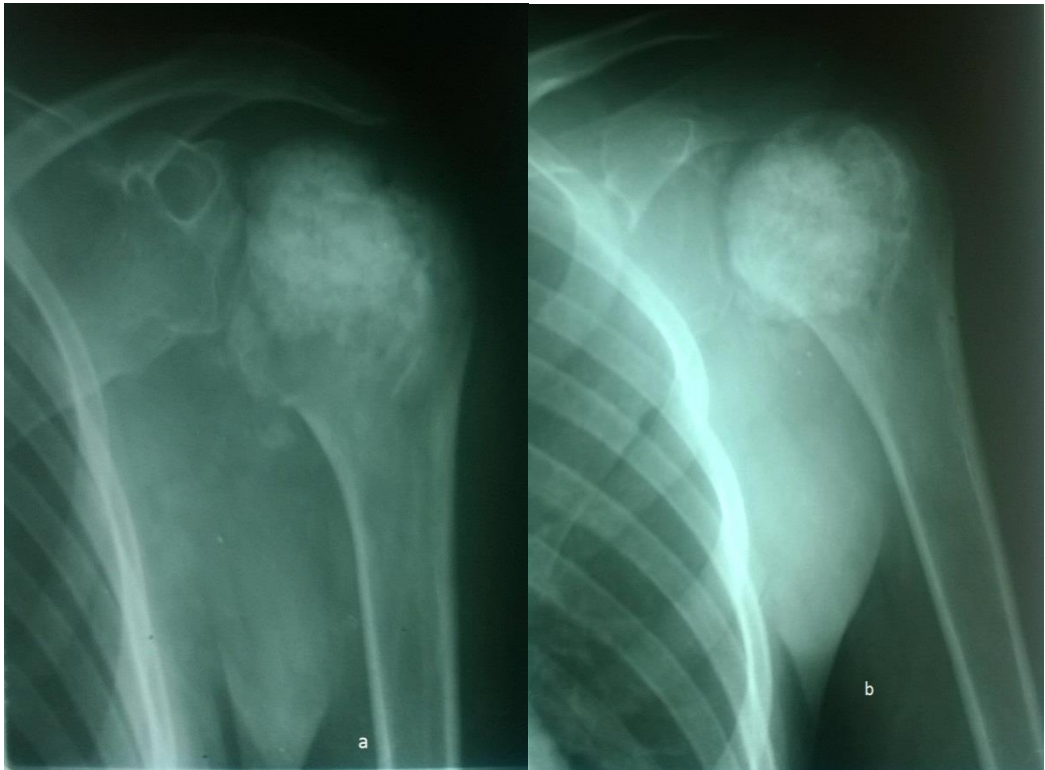


Figure-1. a et b

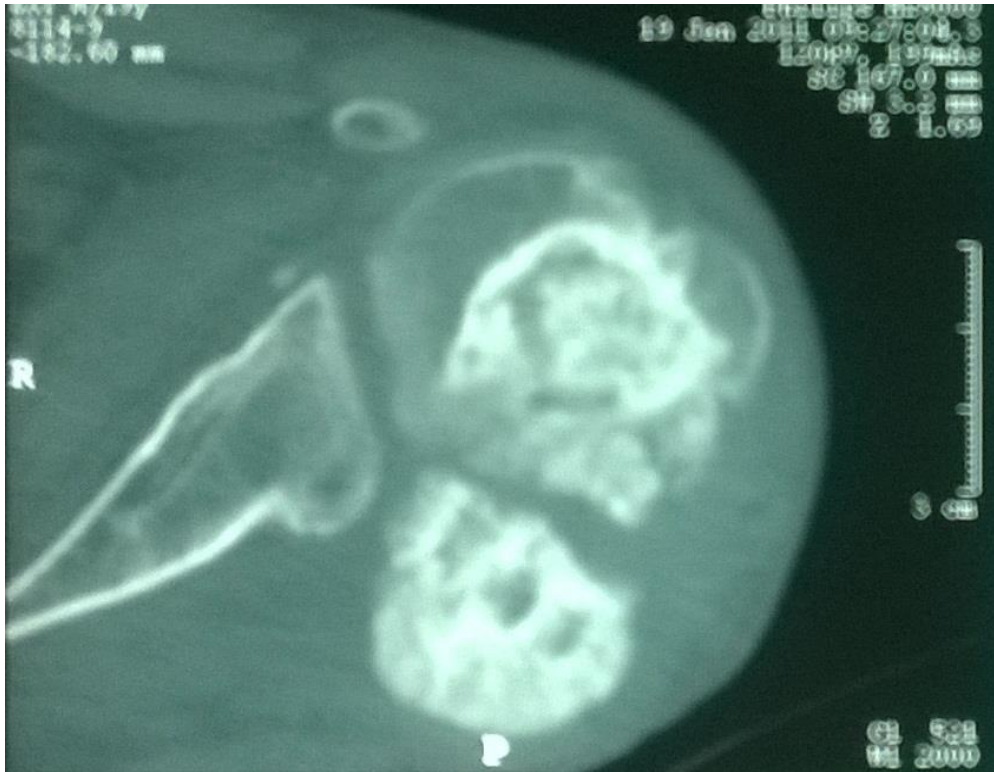

Figure-2.

*Views and opinions expressed in this article are the views and opinions of the author(s), Journal of Diagnostics shall not be responsible or answerable for any loss, damage or liability etc. caused in relation to/ arising out of the use of the content.*