



TREATMENT OF ADAMANTINOMA IN TIBIAL DIAPHYSIS BY HEMICORTICAL RESECTION AND STRUT ALLOGRAFT

Mustafa Nazım Karalezli¹ --- İsmail Hakkı Korucu^{2†} --- Oğuzhan Pekince³ --- Serdar Toker⁴

¹MD. Professor. Necmettin Erbakan University Meram Medicine Faculty Orthopaedics and Traumatology Department, Konya, Turkiye

²MD. Assistant Professor. Necmettin Erbakan University Meram Medicine Faculty Orthopaedics and Traumatology Department, Konya, Turkiye

³MD. Resident. Necmettin Erbakan University Meram Medicine Faculty Orthopaedics and Traumatology Department, Konya, Turkiye

⁴MD. Associate Professor. Necmettin Erbakan University Meram Medicine Faculty Orthopaedics and Traumatology Department, Konya, Turkiye

ABSTRACT

Introduction: Adamantinoma is a primary low-grade, malignant bone tumor, of unknown histogenesis which is a rare neoplasm, comprise only 0.1–0.5% of all primary bonetumors. It is slightly more common in men than women, with a ratio of 5:4. Wide tumour resection and limb salvage is the treatment of choice. Case report: A 24 year female reffered with chief complaints of pain and limping lasting for approximately 2 years. Plain X-ray showed an expansile multicystic lesion at the diaphysis of the left tibia anterior cortex with periosteal reaction . We used an oscillating bone saw to perform a total resection of the lesion preserving the anterior cortex. Tibial defect created with this resection was replaced with a 14 cm. long strut cadaveric femoral allograft that fixed to tibia with a dynamic commpressive plate (DCP) and screws. Discussion: In surgical treatment of Adamantinoma, total resection was not performed and remain intact posterior cortex to increased the patient satisfaction, at the same time, bone fixation and early weight bearing at the postoperative. We believe that the defect will be able to union with appropriate fixation of the allograft also be long size.

Keywords: Adamantinoma, Strut graft, Bone tumor, Hemicortical resection.

1. INTRODUCTION

Adamantinoma is a primary low-grade, malignant bone tumor, of unknown histogenesis which is a rare neoplasm, comprise only 0.1–0.5% of all primary bone tumors [1, 2]. It mostly occurs in the second to fifth decade the median patient age is 25 to 35 years, with a range from 2 years to 86 years. It is slightly more common in men than women, with a ratio of 5:4 [3]. Adamantinoma is associated with a limited propensity for metastasis and local recurrence [4]. Wide tumour resection and limb salvage is the treatment of choice. [5, 6] we aimed that the patient with tibial adamantinoma who underwent using long size allograft hemie cortical resection.

2. CASE REPORT

A 24 year female referred with chief complaints of pain and limping lasting for approximately 2 years. Pain was continuous nature, aggravated by activity and relieved by rest. Physical examination revealed an immobile, fixed and about to 4x6 cm palpable mass on left leg anterior region. Plain X-ray showed an expansile multicystic lesion at the diaphysis of the left tibia anterior cortex with periosteal reaction (fig. 1).

Thorax CT was taken to rule out a possible metastasis and it was normal. Cruris MRI was taken to define the tibial lesion. The mass was localised at the mid-section of the distal tibial diaphyseal cortical bone but also expanded towards the medulla and the adjacent soft tissue. After IVKM nodular-defined level of contrast enhancement is observed in the tubular style (Fig. 2).

We performed incisional biopsy for diagnosis. Pathological examination revealed cytologic properties of adamantinoma. In the histology slides distinct increased fibrous tissue was seen between the bone particles. Within this tissue epithelial cell groups reminiscent of the capillary slides was seen. While immunohistochemical CD31 painting showed positive expression in all capillary endothelium, because formations of lumens or clefts had significant positive expression in certain areas with pancytokeratin painting and many vascular endothelium had no painting these findings were interpreted as adamantinoma. (Fig 3).

Intraoperatively it was confirmed that the lesion localised at the anterior cortex of middle third diaphysis of the tibia and posterior tibial cortex was intact. We used an oscillating bone saw to perform a total resection of the lesion preserving the anterior cortex. Tibial defect created with this resection was replaced with a 14 cm. long strut cadaveric femoral allograft that fixed to tibia with a dynamic compressive plate (DCP) and screws (Fig. 4). The 6th month follow-up x-rays revealed complete bone union. There is no length discrepancy, local recurrence and metastasis at the 15th month follow up. The patient's symptoms resolved completely. (Fig. 5).

There was no metastasis in the thorax CT

3. DISCUSSION

In this case, the patient 24 years old female who had been operated on due to tibia adamantinoma. Adamantinoma is low grade malignant bone tumor. This tumor is rare and also it metastasizes very rarely. The incidence is higher in men than women. [1-3]

In spite of the tumor's local recurrence and metastasize, wide resection and extremity salvage procedure are preferential choice. [7, 8] Many surgical methods are described for reconstruction of the defect. These are; allograft, free vascularized fibula graft, segmental methalised endoprothesis, external fixator asisted bone advancement. [9-11] Often used alograft for reconstruction. [12, 13]

In our case, the patient who underwent hemicortical resection any fracture has not occur in remain cortex of the tibia in intra- postoperatively . Deijkers at all. have reported their 22 cases who underwent hemicortical resection and they have stated fracture on the remaining cortex (3 cases intraoperatively, 3 cases early postoperative period). Deijkers, et al. [14] We used allograft for the defect throughout anterior cortex as well known, allograft using reason for several complication such as infection, nonunion, reoperation. [12, 13] We completed the patient's 15 month follow up. At the final follow up union was completed and the complaints was regressed completely .

In surgical treatment of Adamantinoma, total resection was not performed to increased the patient satisfaction, at the same time, bone fixation and early weight bearing at the postoperative. With this case, at the treatment of Adamantinoma a good view of the lesion's limits and these limits very well defined and carefully verified during total resection surgery can be prevented unnecessary and in this way we think that this procedure can be improved chance of successful treatment. Furtermore, we believe that the defect will be able to union with appropriate fixation of the allograft also be long size.

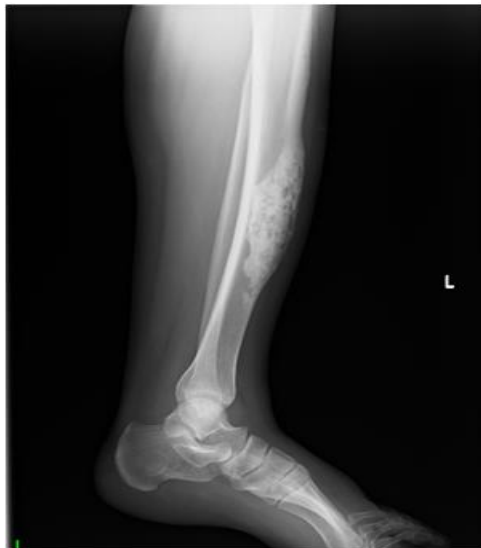

Fig-1. Radiograph showed an expansile multicystic lesion

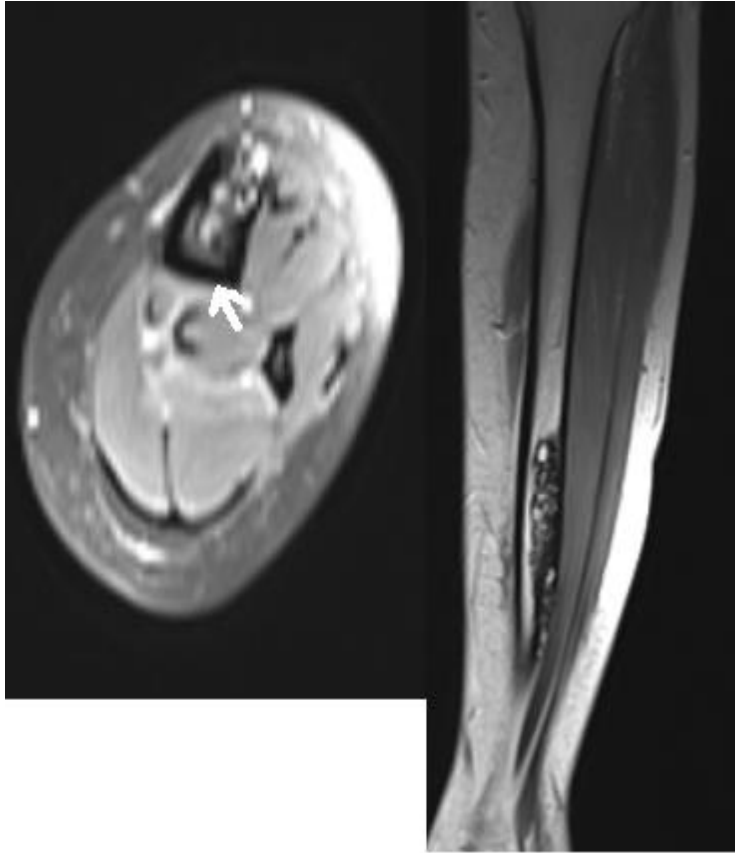


Fig-2. Left cruris MR. Coronal and axial section

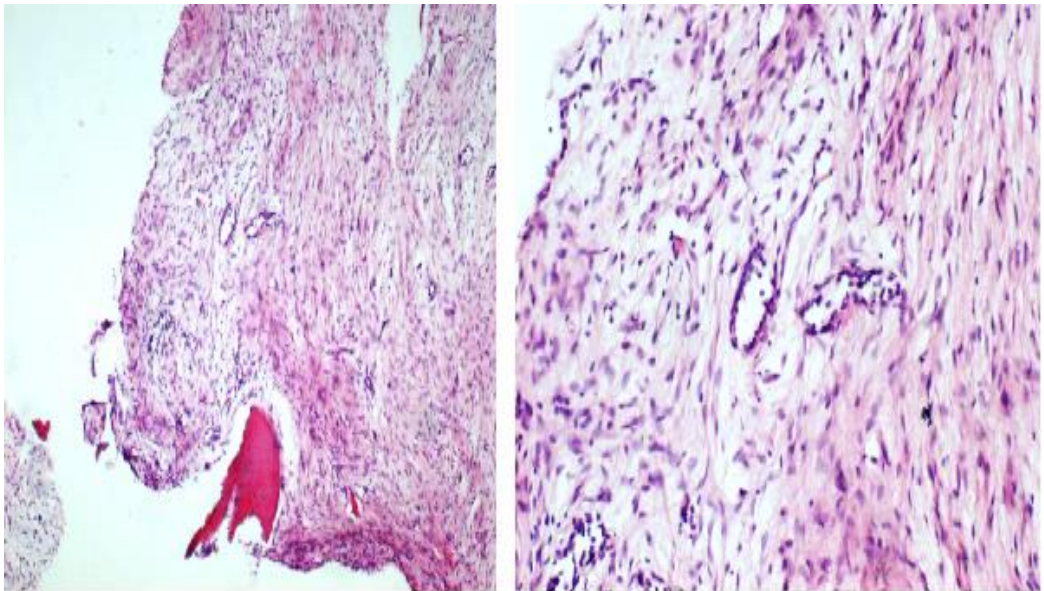


Fig-3. Adamantinoma's finding on pathological sections

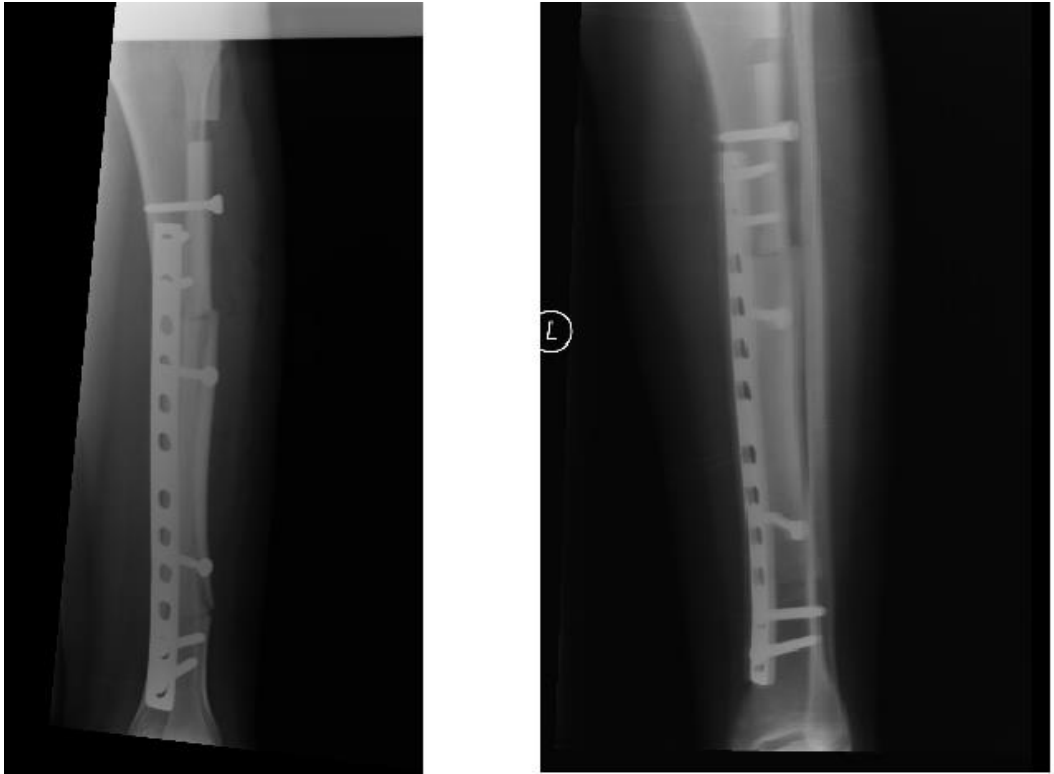


Fig-4. Early postoperative X-ray

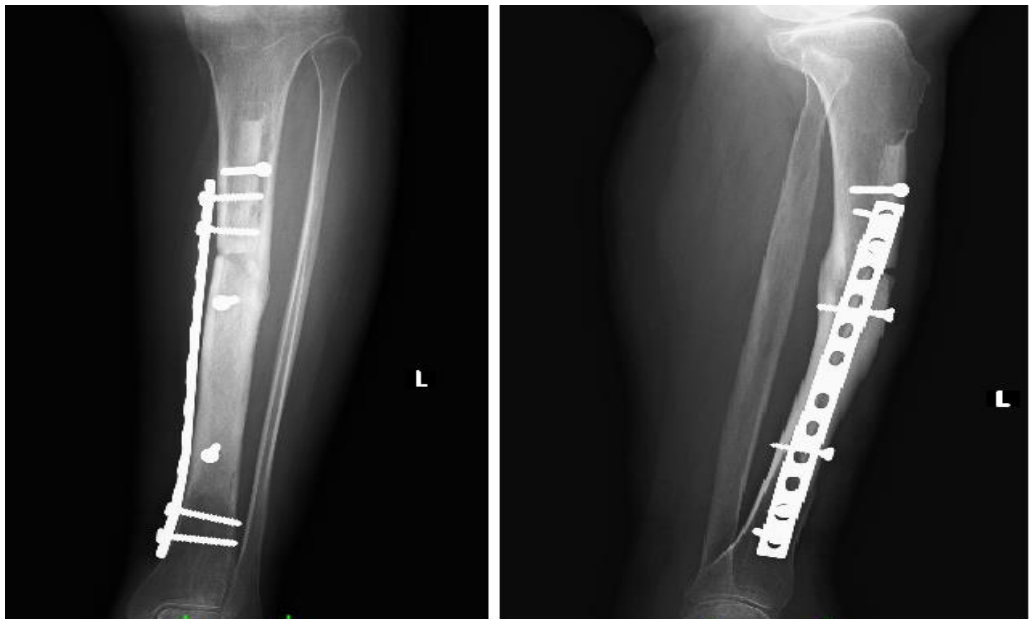


Fig-5.

Fig-5. Completely bone healing after surgery at 15th. month

REFERENCES

- [1] J. Mirra, *Adamantinoma and fibrous dysplasia. Bone Tumors. Clinical, radiologic and pathologic correlations*. Philadelphia: Lea & Febiger, 1989.
- [2] R. Fechner and S. Mils, *Tumors of the bones and joints. In: Atlas of tumor pathology*, 3rd ed. Washington DC: Lippincott-Raven, 1993.
- [3] N. Moon and H. Mori, "Adamantinoma of the appendicular skeleton – updated," *Clin Orthop*, vol. 204, p. 215, 1986.
- [4] A. Qureshi, S. Shott, and B. Mallin, "Current trends in the management of adamantinoma of long bones. An international study," *J Bone Joint Surg Am.*, vol. 82, pp. 1122 – 1131, 2000.
- [5] M. Campanacci, A. Giunti, and F. Bertoni, "Adamantinoma of the long bones. The experience at the Istituto ortopedico Rizzoli," *Am J Surg Pathol.*, vol. 5, pp. 533 – 542, 1981.
- [6] M. Rock, J. Beabout, and K. Unni, "Adamantinoma," *Orthopedics*, vol. 6, pp. 472 – 477, 1983.
- [7] M. Maki and N. Athanasou, "Osteofibrous dysplasia and adamantinoma: Correlation of protooncogene product and matrix protein expression," *Hum Pathol.*, vol. 35, pp. 69 – 74, 2004.
- [8] J. Bovée, L. Van Den Broek, and W. De Boer, "Expression of growth factors and their receptors in adamantinoma of long bones and the implication for its histogenesis," *J Pathol.*, vol. 184, pp. 24 – 30, 1998.
- [9] M. Manfrini, D. Vanel, and M. De Paolis, "Imaging of vascularized fibula autograft placed inside a massive allograft in reconstruction of lower limb bone tumors," *Am J Roentgenol.*, vol. 182, pp. 963 – 970, 2004.
- [10] S. Green, J. Jackson, and D. Wall, "Management of segmental defects by the Ilizarov intercalary bone transport method," *Clin Orthop Relat Res.*, vol. 280, pp. 136 – 142, 1992.
- [11] A. Mavrogenis, V. Sakellariou, H. Tsibidakis, and P. Papagelopoulos, "Adamantinoma of the tibia treated with a new intramedullary diaphyseal segmental defect implant," *J Int Med Res.*, vol. 37, pp. 1238-45, 2009.
- [12] D. Donati, M. Di Liddo, and M. Zavatta, "Massive bone allograft reconstruction in high-grade osteosarcoma," *Clin Orthop Relat Res.*, vol. 377, pp. 186 – 194, 2000.
- [13] R. J. Thompson, A. Garg, and D. Clohisy, "Fractures in large-segment allografts," *Clin Orthop Relat Res.*, vol. 370, pp. 227 – 235, 2000.
- [14] R. Deijkers, R. Bloem, P. Hogendoorn, J. Verlaan, H. Kroon, and A. Taminiau, "Hemicortical allograft reconstruction after resection of low-grade malignant bone tumours," *J Bone Joint Surg (Br)*, vol. 84, pp. 1009-14, 2002.

Views and opinions expressed in this article are the views and opinions of the author(s), Journal of Diagnostics shall not be responsible or answerable for any loss, damage or liability etc. caused in relation to/arising out of the use of the content.