



HEART FAILURE IN A YOUNG LADY: A REVERSIBLE CAUSE

Kaushik Ghosh[†] --- Sunandan Sikdar² --- Susmita Ghosh³ --- Ambarish Bhattacharyya⁴ ---
Sisir Chakraborty⁵ --- Arijit Bag⁶

ABSTRACT

Finding a reversible cause of pulmonary oedema due to left ventricular dysfunction in intensive care unit is very rare. Here we describe such an event in a young lady who has been diagnosed subsequently as Systemic Lupus Erythromatosus with cardiomyopathy and treated successfully. From 'Do Not Resuscitate to 'doing well' this is really an encouraging success story.

Keywords: Systemic lupus erythromatosus, Myocarditis, Pulmonary oedema, Anti nuclear antibody.

Contribution/ Originality

The paper's primary contribution is finding a reversible cause in life threatening Manifestation of a more common disease which adds to our knowledge in existing literature.

1. INTRODUCTION

Systemic Lupus Erythromatosus (SLE) involves multiple organ in its disease course but clinically evident myocarditis or cardiomyopathy is rare. Though myocarditis is not included in diagnostic criteria, this life threatening manifestation may be presenting feature in a previously undiagnosed SLE patients [1]. Pulmonary edema with left ventricular systolic dysfunction in a young woman is a common diagnosis in intensive care setting. It is often attributed to idiopathic non ischemic cardiomyopathy and treated with standard heart failure regimen. However rarely a reversible cause may be found. Finding out a reversible cause of LV dysfunction and treating it appropriately may dramatically alter the natural history. We present here the diagnosis, treatment and outcome of such a case.

1.1. Case Presentation

A twenty two year old woman presented in emergency with pulmonary edema with hypotension for which she was ventilated and started on inotropic support and intravenous diuresis with frusemide. She had a history of treatment for infertility. Her ECG showed sinus

[†] Corresponding author

tachycardia with left ventricular Enlargement. Her Chest X Ray showed pulmonary edema with cardiomegaly. Her Troponin T was 0.1 ng /ml (Normal < 0.01 ng/ml). An echocardiogram revealed global hypokinesia with severe Left Ventricular (LV) systolic dysfunction and an LV Ejection fraction (LVEF) of 25% .Her routine biochemical investigations were normal except a borderline creatinine of 1.5 mg% which was attributed to prerenal cause . She had a haemoglobin of 7.5 gm% which was microcytic, hypochromic and was attributed to iron deficiency. After she was off inotropic support and weaned from ventilator she showed psychotic behaviour. She was transferred out of intensive care unit , but had persistent psychotic behaviour . Her showed urine analysis was normal. In view of her multiple unrelated systemic involvement possibility of autoimmune disease

Was considered. Anti Nuclear Antibody and ds-DNA was positive in high titre 250 and 192 IU/ml her Complement C3 and C4 were low at 66 and 9 respectively (normal range 90-180 and 10-40). Her LDH was 416 . Her Coombs direct and indirect test was negative.

A diagnosis of Sytemic Lupus with myocarditis and cerebral involvement was made. She was started on intravenous Methyl prednisolone 1 gram daily for a week. Her ejection fraction which did not respond to the standard regimen of carvedilol, ramipril and spironolactone showed a dramatic improvement from 25% to 38% Subsequently she was started on oral prednisolone 1mg/kg/day and hydroxychloroquine 200mg/day . By two weeks she was free of orthopnea and though her neuropsychiatric symptoms had improved they were not entirely gone . At one month follow up echocardiography showed a normal LV systolic function. She has neither dyspnea nor any neuropsychiatric symptoms at one month follow up.

2. DISCUSSION

Cardiac involvement is a well recognised manifestation of SLE, and includes pericarditis reported in 50–74% of patients; endocardial involvement in 50–63%, premature atherosclerosis and primary myocardial involvement (myocarditis) in 8–81%, depending on series and diagnostic criteria. Goldblatt, et al. [2] Witejunga et al have described myocarditis in 9% in a more recent series. Wijetunga and Rockson [1] Necropsy studies suggest that myocardial involvement is common, affecting up to 40% of cases, with areas of myocardial inflammation, necrosis, and fibrosis seen.

The gold standard of diagnosing myocarditis in SLE remains endomyocardial biopsy [3]. However, endomyocardial biopsy is an invasive procedure and its diagnostic yield is very low at 10-20%.

Echocardiographic findings in lupus myocarditis include decreased ejection fraction, increased chamber size, prolonged isovolumic relaxation time, decreased diastolic descent rate of the anterior mitral leaflet, decreased ratio of mean systolic velocity to mean diastolic velocity in the left ventricular posterior wall, decreased deceleration of early diastolic flow velocity and reduced E/A ratio, and atrial ejection force [4] Acute lupus myocarditis is a treatable and

reversible cause of systolic dysfunction . Treatment of lupus myocarditis should include an angiotensin-converting enzyme inhibitor and corticosteroids [5]. A high dose of intravenous corticosteroid therapy (e.g., methyl-prednisolone pulses of 1.0 g/day for 5 days) is generally used, followed by an oral preparation (e.g., prednisolone; 1 mg/kg/day) for 1 to 2 weeks. Immunosuppressive agents like azathioprine or cyclophosphamide , and combination of corticosteroids may also be beneficial in the treatment of lupus myocarditis. Additionally, there are some case reports on the beneficial use of intravenous immunoglobulin (IVIG) in lupus myocarditis [6]. In our case, the patient showed resolution of refractory heart failure within a week after high-dose corticosteroid therapy.

3. CONCLUSION

It is imperative to actively search for reversible causes in myocarditis patients as they can significantly alter the prognosis. Lupus myocarditis leading to left ventricular failure responds rapidly to immunosuppressive agents even when standard heart failure regimen gives unimpressive results . In many cases standard clues to the diagnosis like rash, photosensitivity, arthritis may be absent and subtle signs like haematuria and neuropsychiatric manifestation should be carefully analysed. Anti-Nuclear Antibody should be used liberally as a screening test in cases of doubt.

REFERENCES

- [1] M. Wijetunga and S. Rockson, "Myocarditis in systemic lupus erythematosus," *Am. J. Med.*, vol. 113, pp. 419-423, 2002.
- [2] F. Goldblatt, W. Hill, M. J. Ahern, and M. D. Smith, "Shortness of breath in systemic lupus erythematosus: A diagnostic and therapeutic dilemma," *Ann. Rheum Dis.*, vol. 61, pp. 588-590, 2002.
- [3] N. Doherty and R. Siegel, "Cardiovascular manifestations of systemic lupus erythematosus," *Am. Heart J.*, vol. 110, pp. 1257-1265, 1985.
- [4] S. Kalke, C. Balakrishanan, G. Mangat, G. Mittal, N. Kumar, and V. Joshi, "Echocardiography in systemic lupus erythematosus," *Lupus*, vol. 7, pp. 540-544, 1998.
- [5] W. Seong-Ill, H. Gyo-Seung, K. Soo-Jin, P. Jin-Sun, P. Se-Jun, L. Yoon-Seok, L. Yoo-Hong, and T. Seung-Jea, "Lupus myocarditis presenting as acute congestive heart failure: A case report," *J. Korean Med. Sci.*, vol. 24, pp. 176-178, 2009.
- [6] Y. Sherer, Y. Levy, and Y. Shoenfeld, "Marked improvement of severe cardiac dysfunction after one course of intravenous immunoglobulin in a patient with systemic lupus erythematosus," *Clin Rheumatol*, vol. 18, pp. 238-240, 1999.

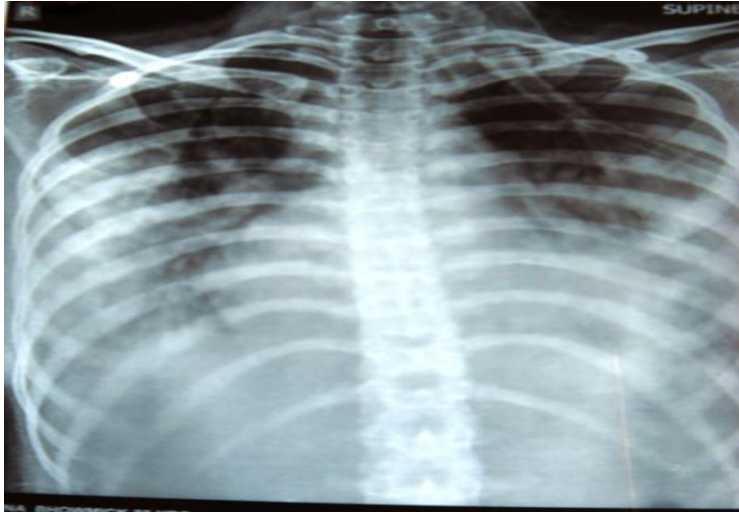

Figure-1. X ray of chest in supine position showing bilateral pulmonary oedema.

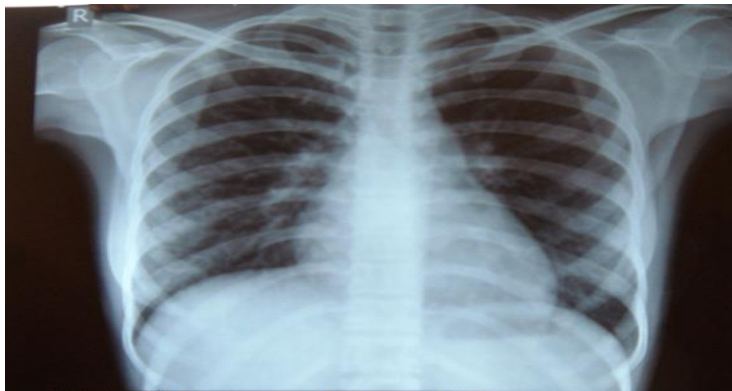


Figure-2. Chest X ray Postero Anterior view after successful treatment

Views and opinions expressed in this article are the views and opinions of the author(s), Journal of Diagnostics shall not be responsible or answerable for any loss, damage or liability etc. caused in relation to/arising out of the use of the content.