



THE SUCCESSFUL TREATMENT OF OBSTRUCTIVE UROPATHY CAUSED BY RETROPERITONEAL FIBROSIS WITH STEROIDS IN THE LATENT TUBERCULOSIS CASE

Yasemin Soyoral^{1†} --- Bulent Ozbay² --- Huseyin Begenik³ --- Mehmet Naci Aldemir⁴ --- Reha Erkoç⁵ --- Deniz Bulut⁶

^{1,5,6}Tuzuncu Yil University Medical Faculty, Department of Internal Medicine, Division of Nephrology, Turkey

²Tuzuncu Yil University Medical Faculty, Department of Chest Disease, Turkey

³Tuzuncu Yil University Medical Faculty, Department of Internal Medicine, Turkey

⁶Tuzuncu Yil University Medical Faculty, Department of Radiology, Turkey

ABSTRACT

Retroperitoneal fibrosis (RPF) is a rare disorder manifested by fibrosis and chronic inflammation in the retroperitoneal tissue. It has been reported that retroperitoneal fibrosis is induced by tuberculosis infection (4). We wanted to present a case of latent tuberculosis, who presented with anuria and developed by bilateral hydronephrosis depending on idiopathic RPF, and treated with steroid therapy, since it is a rare case.

Keywords: Retroperitoneal fibrosis, Postrenal acute renal failure, Latent tuberculosis

1. INTRODUCTION

Retroperitoneal fibrosis (RPF) is a rare disorder manifested by fibrosis and chronic inflammation in the retroperitoneal tissue. Malignancy, radiation exposure and a variety of drugs are caused RPF. However it is idiopathic in two thirds of the cases [1]. Even though it has been suggested that idiopathic RPF is developed due to the local inflammatory response against atherosclerotic plaque antigens formed in abdominal aorta, the coexistence of systemic symptoms and its relationship with some autoimmune diseases suggest that RPF can be retroperitoneal involvement of an inflammatory process [2, 3]. It has been also reported that aortic inflammation is induced by tuberculosis infection [4]. We wanted to present a case of latent tuberculosis, which was applied with anuria and developed by bilateral hydronephrosis depending on idiopathic RPF, and treated with steroid therapy, since it is a rare case.

1.1. Case Report

A 60-year-old male patient has applied to the hospital due to nausea, which was started 4 days ago, vomiting, anorexia and lack of urine. According to the physical examination, the breath sounds were coarse and there were crepitant crackles in the left lung lower lobe. The patient was diagnosed with tuberculosis (TB) with calcified mediastinal lymphadenopathy 12 years ago. 1 month ago, he was revealed mediastinoscopy in another hospital and reported as reactive hyperplasia as a result of the biopsy from the mediastinal lymph nodes (lymphadenopathy) that cause the superior vena cava syndrome. The patient was diagnosed with latent tuberculosis after being consulted by the Chest Diseases clinic. In laboratory values were follows; Hb: 10.4 g/dl, WBC: 12300 /mm³, PLT: 190000 /mm³; the sedimentation rate: 60 mm/hour, CRP: 161 mg/L; urea: 134 mg/dl, creatinine: 7.3 mg/dl, uric acid: 11.6 mg/dl, Na: 145 mmol/L, K: 6.1 mmol/L, Ca: 7.7 mg/dl and pH: 7.3, HCO₃: 18 in the blood gas, respectively. Autoimmune markers and complement levels were normal. In the urinary USG; grade 2 hydronephrosis was present in the right kidney and grade 1 hydronephrosis was present in the left kidney, respectively. Double J catheter was placed to the patient and received dialysis treatment due to the presence of uremic symptoms and anuria. The dialysis treatment was stopped after having a reduced creatinine level of 1.9 mg/dl and urination. An abdominal CT scan and MRI of the patient have been asked to identify the etiology. In the abdominal CT (Figure 1) and abdominal MRI (Figure 2), a soft tissue growth compatible with retroperitoneal fibrosis was observed in the para-aortic and retroperitoneal region. Preaortic, aorticopulmonary window and subcarinal hilar multiple LAPs (larger ones are 32 mm in size) containing calcifications were found in Torax BT. One third of the ureter was deviated to medial. Retroperitoneal biopsy was recommended to the patient. However, the patient did not accept to do so. 15 days later, the patient was taken back to hemodialysis due to the acute renal failure caused by urosepsis. Double J catheter was removed and bilateral nephrostomy catheter was placed. Prednisolone 48 mg/day and Isoniazid (INH) 300 mg/day of TB prophylaxis was started due to retroperitoneal fibrosis. After completing the treatment period up to 6 months, the patient was followed up in our clinic for 3 years with a stable creatinine value (1.3 mg/dl). In addition, no activation of tuberculosis was observed in the patient during these 3 years.

2. DISCUSSION

RPF is a rare disease occurring as a result of chronic inflammation and fibrosis of retroperitoneum. Several findings reveal as a result of this inflammation affecting the organs of abdomen. The disease is found in 50-60 years old males 2 times more than females. The most common symptom of the patients is abdominal pain [5]. They may also apply with lower extremity edema, deep vein thrombosis, arterial complications, constipation, hydrocele, varicocele, polyuria, hematuria and ureteral obstruction even in the late stages [6]. In our case, the patient

was a 60 years old male who applied with anuria and acute renal failure due to ureteral obstruction.

RPF can develop due to some infections such as TB and histoplasmosis [7]. Our patient had a history of previous TB. However, the absence of symptoms such as cough and fever, and presence of calcified mediastinal lymphadenopathies were interpreted as latent tuberculosis .

Steroid treatment was applied with 300 mg of INH prophylaxis to the patient. No activation of tuberculosis was observed in the patient during 3 years of follow up.

The existence of periaortic mass suggests non-Hodgkin lymphomas with especially mediastinal lymphadenopathy [7]. However, in our patient, there were no symptoms such as weight loss or fever, and the biopsies obtained from mediastinal lymphadenopathy were considered as reactive lymphadenopathy. In addition, no symptom such as prostate, testis, renal cell carcinoma etc. was detected that may cause RPF. Furthermore, there was no evidence of abdominal surgery, radiation therapy or retroperitoneal hematoma that may pose a risk to the RPF cases in the history of our patient. Although it has been known that the drugs like methysergide, pergolide, hydralazine and beta-blockers may play a role in the etiology, there was no history of drug use with our patient.

It has been suggested that the mechanism mediated immunity and periaortitis may result in idiopathic RPF. In the literature, it has been reported that a case of retroperitoneal fibrosis induced by tuberculosis, which was completely regressed by antituberculosis treatment [8]. In another case, it has been reported that retroperitoneal fibrosis was detected in the 4th month of the 40 mg of prednisolone treatment period; the patients have applied with active tuberculosis and regressed with antituberculosis treatment. In this study, it has been reported that TB infection may result in RPF by inducing aortic inflammation [4]. In our case, we suggest that periaortic inflammation may be the most possible cause of retroperitoneal fibrosis and previously experienced TB may contribute to this inflammation. In particular, in the endemic regions, where tuberculosis infection is commonly observed, either active or latent TB may be detected in the patients who are diagnosed with RPF. Considering our case and other cases in the literature, we would like to underline that applying immunosuppressive treatment with INH prophylaxis is vital in patients diagnosed with latent TB.

In several studies, renal involvement was reported at very high rates in patients with idiopathic RPF [9-11]. Clinical signs are usually weak in RPF cases. Patients may apply with uremic symptoms due to renal failure developed as a result of ureteral obstruction, which is similar to our case.

According to CT scan of retroperitoneal tissue, increased density in the soft tissue of retroperitoneal area, mass image and withdrawal of the ureter medially are observed. Ultrasound, MRI and IVP are the other methods that can be used for the diagnosis [7]. In our patients, the findings of CT scan, MRI and ultrasound were consistent with RPF. Retroperitoneal mass biopsy

was essential for clarification of the diagnosis. However, since our patient has not accepted to have a biopsy, it couldn't be performed.

In the treatment of RPF patients, it has been aimed to reduce the symptoms caused by the organ primarily affected by thickness of the mass and mass itself and also treat the ureteral obstruction and renal dysfunction. For this purpose, surgery (ureterolysis, intraperitonealization) and medical procedures are performed [5]. Double J catheter was placed to the patient. However, it was removed 15 days later due to the development of urinary tract and nephrostomy catheter was placed instead. Although various drugs are used in the medical treatment, the efficacy of steroid therapy was presented by itself. The aim of steroid treatment is stopping the progression of fibrosis, removing the effect of fibrotic mass and prevention of recurrence [12, 13]. In our patient, the level of creatinine was about 1.3 mg/dl during 3 years of follow up, including 6 months of steroid treatment. Nephrostomy catheter was removed at the 6th month of steroid therapy.

As a result; RPF should be also considered for the patients who applied with anuria and bilateral hydronephrosis. Previously experienced TB may contribute to the development of RPF. In these cases, it should be considered that steroid treatment, applied due to the possible TB activation followed by obstruction repair, may improve renal functions. INH prophylaxis is very important for the patients, who are diagnosed with latent TB and will be receiving steroid treatment, in order to prevent the activation of tuberculosis.

REFERENCES

- [1] G. Bennur Esen, D. Tuncay, D. İbrahim, and K. Serdar, "Retroperitoneal fibrozise bağlı bilateral hidronefroz ve steroid tedavisine yanıt: Olgu Sunumu," *İstanbul Tıp Derg-İstanbul Med. J.*, vol. 12, pp. 187-190, 2011.
- [2] A. Vaglio, D. Corradi, L. Manenti, S. Ferretti, G. Garini, and C. Buzio, "Evidence of autoimmunity in chronic periaortitis: A prospective study," *Am. J. Med.*, vol. 114, pp. 454-62, 2003.
- [3] R. De, J. Serratrice, B. Granel, P. Disdier, J. Bartoli, X. Pache, P. Astoul, L. Garbe, A. Branchereau, and P. Weiller, "Periaortitis heralding wegener's granulomatosis," *J. Rheumatol*, vol. 29, pp. 392-4, 2002.
- [4] C. Molloy, C. Filer, and A. Ismail, "Mycobacterium tuberculosis as a cause of chronic periaortitis," *Rheumatology (Oxford)*, vol. 44, pp. 696-7, 2005.
- [5] H. Liu, G. Zhang, Y. Niu, N. Jiang, and W. Xiao, "Retroperitoneal fibrosis: A clinical and outcome analysis of 58 cases and review of literature," *Rheumatol Int.*, vol. 34, pp. 1665-70, 2014.
- [6] A. Vaglio, C. Salvarani, and C. Buzio Lancet, "Retroperitoneal fibrosis," *Lancet*, vol. 367, pp. 241-51, 2006.
- [7] M. Tzou, D. Gazeley, and P. Mason, "Retroperitoneal fibrosis," *Vasc Med.*, vol. 19, pp. 407-414, 2014.

- [8] P. Greco, A. Vaglio, D. Corradi, R. Cobelli, M. Zompatori, and C. Buzio, "Tuberculosis as a trigger of retroperitoneal fibrosis," *Clin. Infect Dis.*, vol. 41, pp. e72-5, 2005.
- [9] K. Li, J. Zhu, J. Zhang, and F. Huang, "Idiopathic retroperitoneal fibrosis (RPF): Clinical features of 61 cases and literature review," *Clin Rheumatol*, vol. 30, pp. 601-5, 2011.
- [10] C. Ilie, R. Pemberton, and D. Tolley, "Idiopathic retroperitoneal fibrosis: The case for nonsurgical treatment," *BJU Int.*, vol. 98, pp. 137-140, 2006.
- [11] A. Fry, S. Singh, and S. Gunda, "Successful use of steroids and ureteric stents in 24 patients with idiopathic retroperitoneal fibrosis: A retrospective study," *Nephron Clin. Pract.*, vol. 108, pp. 213-220, 2008.
- [12] E. Van Bommel, C. Siemes, and L. Hak, "Long-term renal and patient outcome in idiopathic retroperitoneal fibrosis treated with prednisone," *Am. J. Kidney Dis.*, vol. 49, pp. 615-625, 2007.
- [13] A. Kardar, S. Kattan, E. Lindstedt, and K. Hanash, "Steroid therapy for idiopathic retroperitoneal fibrosis: Dose and duration," *J. Urol.*, vol. 168, pp. 550-555. 10, 2002.

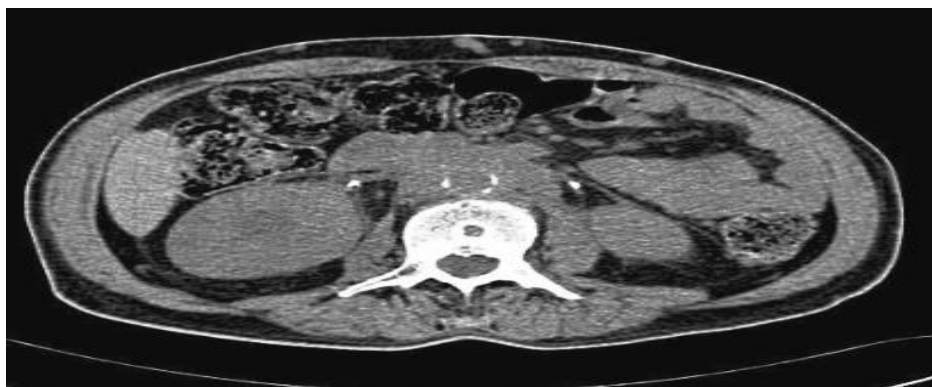

Figure-1. RPF BT

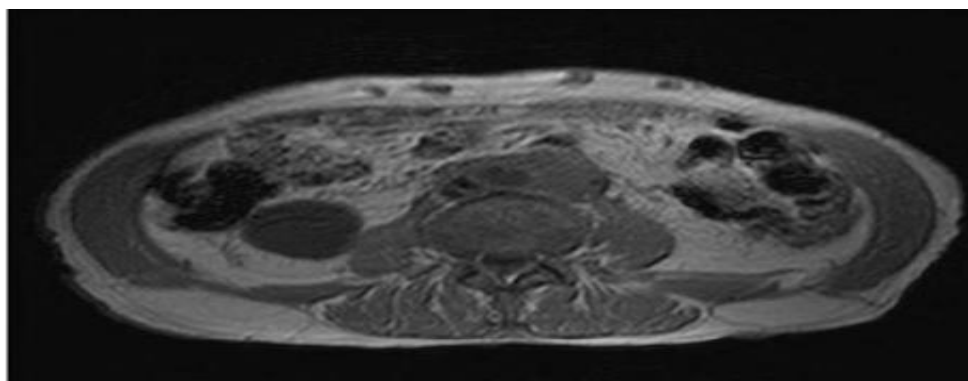


Figure-2. RPF MR

Views and opinions expressed in this article are the views and opinions of the author(s), Journal of Diagnostics shall not be responsible or answerable for any loss, damage or liability etc. caused in relation to/arising out of the use of the content.