



## RENAL-BIOFUNCTION POTENTIALS OF ETHANOLIC EXTRACT OF *Solanum Melongena* LINN FRUIT ON MONOSODIUM GLUTAMATE- INTOXICATED RATS' AND KIDNEY HISTOLOGY

Uchendu O.

Mbah<sup>1\*</sup>

Anthony Cemaluk

C. Egbuonu<sup>2</sup>

Ijere D. Nwanne<sup>3</sup>

Obinna Jeremiah<sup>4</sup>

<sup>1,2</sup>Department of Biochemistry, College of Natural Sciences, Michael Okpara University of Agriculture Umudike, Abia State, Nigeria

<sup>1</sup>Email: [mhaokurwa@gmail.com](mailto:mhaokurwa@gmail.com)

<sup>2</sup>Email: [tonycemalukegbuonu@yahoo.com](mailto:tonycemalukegbuonu@yahoo.com)

<sup>3</sup>Department of Biotechnology, School of Biological Sciences, Federal University of Technology, Owerri, Imo State, Nigeria

Email: [nwannejere@yahoo.com](mailto:nwannejere@yahoo.com)

<sup>4</sup>Department of Biology/Microbiology, School of Science and Industrial Technology, Abia State Polytechnic, Aba, Abia State, Nigeria

Email: [Obinnajeremiah15@gmail.com](mailto:Obinnajeremiah15@gmail.com)



(+ Corresponding author)

### ABSTRACT

#### Article History

Received: 4 December 2018

Revised: 10 January 2019

Accepted: 13 February 2019

Published: 7 March 2019

#### Keywords

*Solanum melongena* linn fruit

MSG –intoxication

Renal biofunction

Kidney

Histology

Ethanollic extract

Ameliorative potentials.

This study evaluated the renal biofunction potentials of ethanolic extract of *Solanum melongena* Linn fruit on monosodium glutamate-intoxicated rats' and kidney histology using standard protocol. Twenty four Wistar rats that weighed  $105.00 \pm 7.00$  g were used. The rats were assigned into 6 groups of 4 each and fed thus: Group 1 (control, feed and distilled water only), Group 2 (8000mg/kg body weight monosodium glutamate (MSG)), Group 3 (300mg/kg body weight (bw) the sample extract), Group 4 (8000mg/kg bw MSG + 100mg/kg bw the sample extract), Group 5(8000mg/kg bw MSG+ 300mg/kg bw the sample extract) and Group 6 (8000mg/kg bw MSG+ 500mg/kg bw the sample extract) daily for 14 days. The results were expressed as mean  $\pm$  S.E.M and one-way analysis of variance (ANOVA), followed by a Duncan posthoc test was done to test for significance using SPSS version 22.0. The exposure of MSG resulted in a significant ( $P = 0.05$ ) increase in the activities of serum urea, creatinine, potassium ion, chloride ion, and sodium ion compared to the control. MSG and ethanolic extract of *Solanum melongena* Linn fruit co-treated groups at different concentrations were significantly ( $P = 0.05$ ) reduced to become comparable to the control group. MSG consumption in high concentration alters renal biofunction and this is also evident in the histology of the studied rats' kidney sections. However, the protective roles of ethanolic extract of *Solanum melongena* Linn fruit were notably at 500mg/kg of body weight in rats, a pointer to the dose-dependent function.

**Contribution/Originality:** This research underscores the possible MSG-intoxication effects on the renal system in high concentration be it inadvertently or not and as well as the possible ameliorative roles of *Solanum melongena* Linn fruit on the affected organ on a dose-dependent function.

### 1. INTRODUCTION

*Solanum* species (eggplants) belong to the family of *Solanaceae* and the plant genus *Solanum*. *Solanum melongena* is an economically important vegetable crop that is widely cultivated in the tropical region and a good source of vitamins, minerals, free water and phytochemicals [1-3]. This family includes fruits and vegetables such as potato (*Solanum tuberosum* L.), tomato, peppers and other medicinal plants like *Atropa belladonna* L. (deadly

nightshade) and *Hyoscyamus niger*. The leaves and fruits of *Solanum melongena* serve as vegetables and are used in traditional medicine [4]. *Solanum melongena* fruit is usually cooked to make soup or stew especially in the southern and western parts of Nigeria [1]. The extracts of *Solanaceae* were effective antibacterial [5-7] and acts as an antioxidant, owing to its phytochemical contents [3, 7, 8] antidiabetic [9, 10] hypolipidaemic agent [11, 12] cardioprotective with haema-improvement roles [12] and a hepatoprotective agent [13].

Monosodium glutamate (MSG), the sodium salt of glutamate is a food additive generally used to improve flavour in foods. MSG has been accepted worldwide as a flavour enhancer and is approved without a daily recommended range as it is generally regarded as a safe product by regulatory bodies even with numerous reported possible adverse effects it could result to Mbah and Egbuonu [12]; Akanya, et al. [14]. Flavourings are important in savoury food manufacturing particularly those dealing more on spicy foods as it provides its Umami taste. One could be consuming these foods in high quantities without consideration to the effects of MSG inadvertent use. There has been a report of possible liver dysfunction upon consumption of MSG in high concentration [13, 15, 16] enhanced appetite and food intake that could lead to obesity and even excitotoxicity in cells via its catabolic product; glutamate [17, 18]. Others reported the adverse influence of MSG in animals to include impaired lipid metabolism and cardiac function [12, 17] which could induce oxidative stress [3, 19] and alter renal function [15, 17].

The kidneys are bean-shaped organs that are located just below the rib cage in the middle of the back. They are vital life-sustaining organs performing many functions to keep the blood clean and chemically balanced. The kidney does the following functions; filter the blood to get rid of waste products of metabolism, control the electrolytes composition and water content of the body and secrete a number of essential hormones. These functions underscore the need to maintain a functional kidney. However, the consumption of MSG in high concentration may affect the vital function of the nephrons, resulting in severe pathologies [15, 20]. Hence it is important to evaluate the renal biofunction potentials of the ethanolic extract of *Solanum melongena* Linn fruit on MSG-intoxicated Wistar rats' and kidney sections histology.

## 2. MATERIALS AND METHODS

### 2.1. Plant Materials and Preparations

Matured eggplant fruits were bought in a local market: Ehere market in Aba, Abia State in the fruiting season of May, 2016. The fruit was identified as *Solanum melongena* Linn in the Plant Science and Biotechnology Department, Michael Okpara University of Agriculture, Umudike, Abia State, Nigeria. The fruits were washed with clean tap water, cut into smaller pieces using a knife and air-dried for two weeks then milled into powdered form using a laboratory miller and stored in an airtight container. □

### 2.2. Extraction and Concentration

The powder (4kg) was immersed in 3000 ml of absolute ethanol for 72 hours with interval shaking. The extract was filtered with No 1 Whatman filter paper. The filtrate was concentrated using a water bath at 60°C and was further dried in an oven set at 50°C. The extract yield was 1.54% w/w. The extract was placed into a sample bottle and stored at 4°C in the refrigerator until it was required for the experiment. The ethanol extract of *Solanum melongena* Linn fruit was then dissolved in water and prepared into three different doses (Low dose; 100mg/kg body weight of the extract; Middle dose; 300mg/kg body weight of the extract, High dose; 500mg/kg body weight of the extract) for administration while monosodium glutamate was also dissolved in distilled water to make an aqueous solution. The previous report by Thomas, et al. [21] formed the basis for the experimental chosen dose of 8000mg/kg body weight MSG for the intoxication of the rats for 14 days.

### 2.3. Reagents and Chemicals

Reagents used for all the experiments were commercial kits and products of Randox, (USA) and Teco (TC), (USA).

### 2.4. Animal Study Design

Twenty-four periadolescent Wistar rats of mean body weight  $105.00 \pm 7.00$  g, was obtained from the animal breeding unit of the College of Veterinary Medicine, Michael Okpara University of Agriculture, Umudike. The animals were kept in appropriate cages and in a well-ventilated room with free access to standard feed and clean tap water under room temperature with a 12 hour day/night cycle throughout the period of the experiment. All the animals received humane care in accordance with the guidelines of the National Institute of Health, USA for ethical treatment of laboratory animals [22]. This guideline was approved by the ethical committees of the Department of Biochemistry and college of Natural science Michael Okpara University of Agriculture, Umudike, Nigeria. The animals were randomly grouped into six of four animals each, (as shown below) after one week of acclimatization. The rats were fed with vital feed grower mash and were given water *ad libitum* during acclimatization and through the exposure duration. The MSG (99% min) FCC grade E621 used is a product of Meihua group, China.

The animals received the treatment as given below;

**Group 1:** Feed + 1 ml/kg bw of distilled water only.

**Group 2:** 8000 mg/kg bw of MSG only.

**Group 3:** 300 mg/kg bw of ethanolic extract of *Solanum melongena* Linn fruit.

**Group 4:** 8000 mg/kg bw of MSG + 100 mg/kg bw ethanolic extract of *Solanum melongena* Linn fruit.

**Group 5:** 8000 mg/kg bw of MSG + 300 mg/kg bw ethanolic extract of *Solanum melongena* Linn fruit.

**Group 6:** 8000 mg/kg bw of MSG + 500 mg/kg bw ethanolic extract of *Solanum melongena* Linn fruit.

The treatment was per-oral (using orogastric tube) and was administered daily for 14 days. At the end of the experiment, after an overnight fast, the rats were sacrificed to obtain blood samples by cardiac puncture using sterile capillary tubes (containing no anticoagulant). Blood samples were separately centrifuged for 10 minutes at 3,000 rpm at room temperature, and the serum was separated and stored in a deep freezer for the determination of the concentration of urea, creatinine, sodium ion, chloride ion and potassium ion in the rats' serum. □

### 2.5. Renal Function Parameters

#### 2.5.1. Serum Urea Determination

The serum urea was determined by the method described by Weatherburn [23]. This method is based on the principle that urea in serum is hydrolysed to ammonia in the presence of urease. The ammonia is then measured spectrophotometrically using UV-VIS Spectrophotometer Labomed UV-250 by Berthelot reaction at 546nm.

#### 2.5.2. Serum Creatinine Determination

The serum creatinine was determined by the method described by Henry, et al. [24]. This method was based on the principle that creatinine reacts with picric acid in alkaline conditions to form a colour complex which absorbs at 510nm and measured using UV-VIS Spectrophotometer Labomed UV-250. The rate of formation of colour is proportional to the creatinine concentration in the sample. □

#### 2.5.3. Serum Chloride Ion Concentration

The concentration of serum chloride ion (Cl<sup>-</sup>) was determined using the method of Skeggs and Hochstrasser [25]. This method is based on the principle that chloride ions form a soluble, non-ionized compound. When

reacted with mercuric ions they would displace thiocyanate ions from non-ionized mercuric thiocyanate. The released thiocyanate ions reacted with ferric ions to form a coloured complex that absorbed light at 480nm. The intensity of the colour produced was directly proportional to the chloride ion concentration.

#### 2.5.4. Serum Potassium Ion Concentration

The concentration of serum potassium ion ( $K^+$ ) was determined using the turbidometric method as described by Henry, et al. [24]. The amount of potassium was determined by using Sodium tetraphenylboron in a specifically prepared mixture to produce a colloidal suspension; the extent of turbidity is proportional to the potassium concentration and is measured spectrophotometrically using UV-VIS Spectrophotometer Labomed UV-250 at 578nm.

#### 2.5.5. Serum Sodium Ion Concentration

Serum sodium ion ( $Na^+$ ) concentration was estimated using colorimetric method based on modified Maruna and Trinders method as described by Trinder [26]. This method is based on the principle that sodium and proteins are precipitated together by magnesium uranyl acetate as uranyl magnesium sodium acetate salt. Excess of uranyl salt reacts with potassium ferrocyanide to produce a brownish colour. The intensity of the colour is inversely proportional to the sodium concentration in the specimen and is measured spectrophotometrically using UV-VIS Spectrophotometer Labomed UV-250 at 530nm.

#### 2.6. Histopathological Examination

The histopathological examination of the liver tissues of Wistar rats were done using the method of Drury, et al. [27]. This procedure requires the following: fixation and washing of the tissues, dehydration, clearing with xylene, infiltration with paraffin, embedding with paraffin, paraffin section, mounting, staining with haematoxylin and microscopic observation of the slides at x400 magnification.

#### 2.7. Statistical Analysis

Collected data were subjected to statistical Analysis of Variance (ANOVA) with the statistical package for the social sciences (SPSS) for Windows version 22.0 SPSS Inc [28]. The Duncan posthoc test was used to identify the means that differed significantly at  $P=0.05$ . Results were expressed as Mean  $\pm$  standard error of the mean (SEM).

### 3. RESULTS

**Table-1.** Effects of daily treatment of rats with mono-sodium glutamate (8000mg/kg bw) and ethanolic extract of *Solanum melongena* Linn fruit at different concentration (100, 300 and 500mg/kg bw) on some renal function parameters.

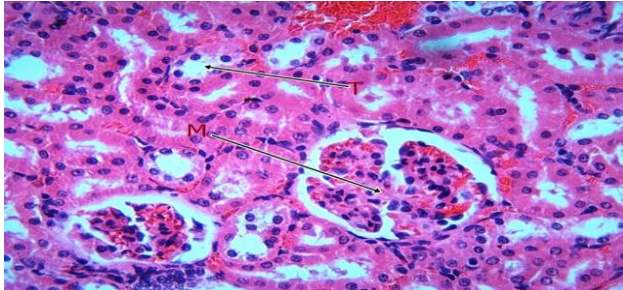
PARAMETERS	Urea (mg/dl)	Creatinine (mg/dl)	Potassium (mEq/L)	Chloride (mEq/L)	Sodium (mEq/L)
Group 1	29.23 $\pm$ 0.84	1.13 $\pm$ 0.02	4.01 $\pm$ 0.08	84.81 $\pm$ 2.78	135.30 $\pm$ 1.41
Group 2	43.31 $\pm$ 1.35*	3.27 $\pm$ 0.15*	6.01 $\pm$ 0.08*	113.98 $\pm$ 1.32*	162.75 $\pm$ 1.81*
Group 3	31.44 $\pm$ 1.56	1.14 $\pm$ 0.02	4.01 $\pm$ 0.05	92.45 $\pm$ 1.56	138.23 $\pm$ 0.02
Group 4	34.93 $\pm$ 1.20	1.08 $\pm$ 0.03	5.02 $\pm$ 0.12	102.35 $\pm$ 3.73*	146.79 $\pm$ 2.60
Group 5	34.04 $\pm$ 1.38	1.20 $\pm$ 0.03	4.85 $\pm$ 0.16	102.45 $\pm$ 2.12*	141.00 $\pm$ 6.22
Group 6	33.39 $\pm$ 0.81	1.17 $\pm$ 0.05	5.18 $\pm$ 0.12	102.95 $\pm$ 1.73*	139.75 $\pm$ 5.44

Values are expressed as mean  $\pm$ SEM for four replications. \*values are significantly different at ( $P=0.05$ ).

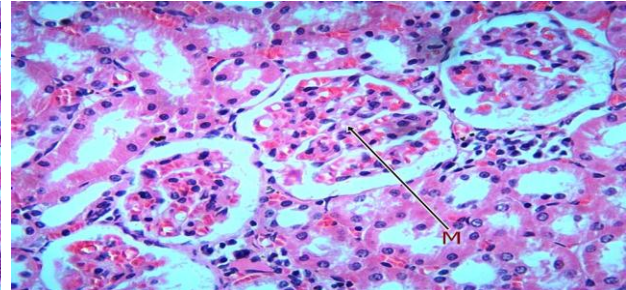
Table 1 showed the determined serum urea, creatinine, potassium ion, chloride ion and sodium ion concentrations. For the group 2, the serum urea, creatinine,  $K^+$ ,  $Cl^-$  and  $Na^+$  concentrations (43.31  $\pm$  1.35mg/dl, 3.27  $\pm$  0.15mg/dl, 6.01 $\pm$  0.08mEq/l, 113.98  $\pm$  1.32mEq/l and 162.75  $\pm$  1.81mEq/l respectively) were significant

( $P=0.05$ ) when compared to groups 3,4,5,6 and the control group. Furthermore, the serum urea, creatinine,  $K^+$  and  $Na^+$  concentrations were not significant ( $P=0.05$ ) for groups 3, 4, 5 and 6 except for the serum  $Cl^-$  whose values for groups 4, 5 and 6 were significantly ( $P=0.05$ ) higher compared to the control group.

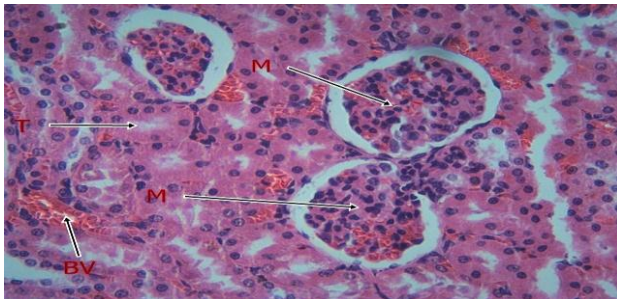
### 3.1. Histology Result (H & E X400)



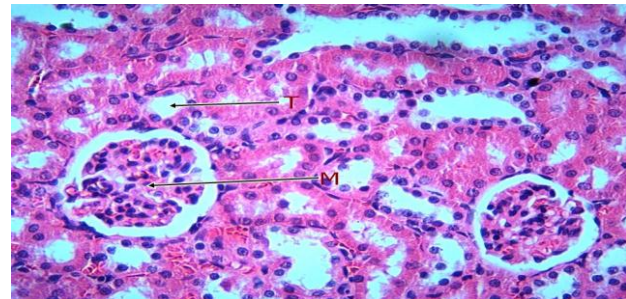
**Plate-1.** Photomicrograph of kidney section from rats in normal control (Group 1) showing evenly distributed open glomerular capillaries, and moderate interstitial haemorrhage.



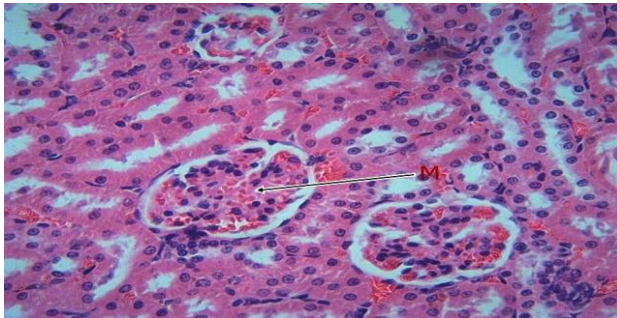
**Plate-2.** Photomicrograph of the kidney section from rats treated with MSG (Group 2) showing mesangial hypercellularity consisting of mononuclear inflammatory cells and proliferating mesangial cells and moderate interstitial haemorrhage.



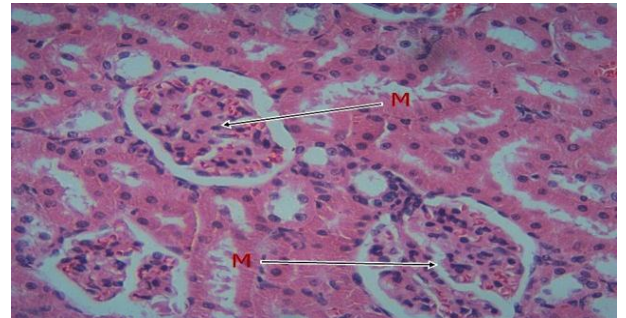
**Plate-3.** Photomicrograph of the kidney section from rats treated with plant extract (Group 3) showing evenly distributed open glomerular capillaries, normal endothelium and moderate interstitial haemorrhage.



**Plate-4.** Photomicrograph of the kidney section from rats treated with MSG and 100mg/kg of the plant extract (Group 4) showing evenly distributed open glomerular capillaries with mesangial hypercellularity and moderate interstitial haemorrhage.



**Plate-5.** Photomicrograph of the kidney section from rats treated with MSG and 300mg/kg of the plant extract (Group 5) showing evenly distributed open glomerular capillaries with moderate interstitial haemorrhage.



**Plate-6.** Photomicrograph of the kidney section from rats treated with MSG and 500mg/kg of the plant extract (Group 6) showing evenly distributed open glomerular capillaries with normal endothelium. There is also moderate interstitial haemorrhage.

## 4. DISCUSSION

Biochemical markers play an important role in objective measurement and evaluation of how different organs functions, in response to the normal biological or pathological state. Urea, creatinine and electrolytes are used in the assessment of kidney function. This study revealed that high MSG exposure in rats alters renal function parameters. There is a significantly ( $P=0.05$ ) higher serum urea and creatinine concentration in the MSG only fed group compared to the control group. This reflects induced-toxicity that compromised the kidney function [15] and is in line with reported findings by Egbuonu and Oriji [20] which speculated that MSG intoxication may be due to free sodium interaction with the cells; which may have led to the altered kidney biofunction

observed in MSG only fed the group. This result also agrees with the report by Inuwa, et al. [29]. Urea is the major nitrogen end-product of proteins and amino acid catabolism; its impairment could have resulted from down-regulation of the urea cycle and other non-renal factors like diets while creatinine is a product of creatine phosphate kinase breakdown in muscles. It is produced at a fairly constant rate by the body in relation to the individual muscle mass. However, creatinine does not depend on renal factors like diet and urea cycle enzymes [15]. It is influenced by muscle function, composition, activities and health status. These observed increases in urea and creatinine concentrations are indicators of poor glomerular filtration rate (GFR). Recall the groups 3, 4, 5 and 6 showed no significant difference ( $P = 0.05$ ) compared to the control group. This revealed that the extract may have ameliorated the MSG-induced toxic responses in the rats at those different dosages [3, 7, 12, 13]. Nevertheless, a closer look at the histology results apparently revealed that the ethanol extract mitigated the intoxication better at 500mg/kg body weight. Electrolytes monitor acid-base imbalance. Intake of dietary MSG in rats altered some physiological functions of the kidney. From this present study, the  $K^+$ ,  $Na^+$  and  $Cl^-$  were significantly ( $P=0.05$ ) higher for the MSG only fed rats (group 2) compared to the control group, the extract fed group and MSG plus extract fed groups (groups 3,4,5 and 6) at different dosages. This suggests an impaired kidney function indicated by hypernatremia and hyperkalemia. Sodium is the primary solute in the extracellular fluid. Sodium levels have a major role in osmolarity regulation and for some excitable cells the electrochemical gradient for sodium across the plasma membrane through sodium ATPase pump is critical for life as  $Na^+$  is required to regulate blood pressure. Chloride is the major anion found in the fluid outside of cells and in the blood. Chloride ion is needed to control hydration and acid balance while Potassium is the major cation found inside of cells.  $K^+$  which is required to regulate fluid balance in the body, regulate heartbeat and muscle tones were all increased. However, these findings do not totally agree with the report by Inuwa, et al. [29] who reported no significant difference for  $K^+$ ,  $Na^+$  and  $Cl^-$ . These differences could be accounted on the basis of the MSG concentrations and the rate of exposure. Akanya, et al. [14] reported in a preliminary study that as MSG concentration increases, there would be a corresponding increase in the concentration of electrolytes excreted and the same was observed from other reports [16, 20]. Potassium homeostasis may also be altered by changes in acid-base balance, insulin and aldosterone and this may result in its poor excretion since it can only be done via the renal system. This report by Akanya, et al. [14] appears to be true from this finding. Nevertheless, there were no significant differences for the groups 3, 4, 5, and 6 between the groups for the different parameters. This suggests that the integrity of the normal renal capacity to excrete electrolytes, which were compromised, could be ameliorated by ethanol extract *Solanum melongena* Linn fruit on a dose-dependent treatment. □

The histomorphological changes in the sections of the kidney (Plate for groups 4, 5 and 6) revealed the gradual regeneration of open glomerular capillaries with mesangial hypercellularity and inflammation that was observed in group 2 (Plate from group 2). However, moderate interstitial haemorrhage was observed in all the groups. The rats' kidney histology was observed to correlate with the serum kidney and electrolytes results. Eweka [30] reported of the varying degree of cyto-architectural distortion and reduction in the number of renal corpuscle, degenerative and atrophic changes in the MSG treated rats groups compared with the control group. This finding is in line with the outcome of this present study. These observed effects could have resulted from oxidative stress condition generated by MSG, possibly via its catabolic intermediates, though this possible mechanism has not been fully elucidated [3] however, it altered filtration ability of the glomerulus. Nevertheless, the function of the glomerulus was restored and improved upon exposure to ethanol extract of *Solanum melongena* Linn fruit at 500mg/kg body weight as it appears, a confirmation of the renal biofunction protective potentials of extract of *Solanum melongena* Linn fruit which is dose dependent and better administered at the highest examined dose.

## 5. CONCLUSION

On a daily basis, MSG is continually consumed. However, at a high concentration, it may alter the renal biofunction and this is also evident in the histology of the studied rats' kidney sections. However, the reno-protective potentials of the extract of *Solanum melongena* Linn fruit was notably at 500mg/kg of body weight in rats. Thus, underscores the usefulness of ethanol extract of *Solanum melongena* Linn fruit in the management and possibly treatment of MSG intoxication in rats' kidney function.

**Funding:** This study received no specific financial support.

**Competing Interests:** The authors declare that they have no competing interests.

**Contributors/Acknowledgement:** Thank you, Solomon N. Ijioma and Mr. Akankwu Samuel for their wonderful contributions toward the success of this research study.

## REFERENCES

- [1] S. N. Chinedu, A. C. Olasumbo, O. K. Eboji, O. C. Emiloju, O. K. Arinola, and D. I. Dania, "Proximate and phytochemical analyses of solanum aethiopicum L. and solanum macrocarpon L. fruits," *Research Journal of Chemical Sciences*, vol. 1, pp. 63-71, 2011.
- [2] B. Agoreyo, E. Obansa, and E. Obanor, "Comparative nutritional and phytochemical analyses of two varieties of solanum melongena," *Science World Journal*, vol. 7, pp. 5-8, 2012.
- [3] U. O. Mbah and A. C. C. Egbuonu, "Ethanol extract of solanum melongena Linn fruit mitigated monosodium glutamate-induced oxidative stress," *International Journal of Biochemistry Research & Review*, vol. 18, pp. 1-8, 2017. Available at: <https://doi.org/10.9734/ijbcrr/2017/35055>.
- [4] K. O. Bonsu, D. A. Fontem, G. O. Nkansah, R. N. Iruome, E. O. Owusu, and R. R. Schippers, "Diversity within the gboma eggplant (*Solanum macrocarpon*), an indigenous vegetable from West Africa," *Ghana Journal of Horticulture*, vol. 1, pp. 50-58, 2008.
- [5] A. S. Madhuri, R. T. Sandhya, H. N. Naeim, and S. A. Jai, "Antimicrobial activity of the leaf extracts of solanum melongena," *International Journal of Pharmaceutical Research & Review*, vol. 4, pp. 1-5, 2015.
- [6] S. Amutha, "Screening of antibacterial activity of solanum melongena seed extracts on selected human pathogenic bacteria," *International Journal of Pharma and Bio Sciences*, vol. 5, pp. 208-213, 2014.
- [7] U. O. Mbah, A. C. C. Egbuonu, O. D. Omodamiro, O. Jeremiah, and I. D. Nwanne, "In vitro antioxidant and antimicrobial activity of ethanol extract of egg plant (*Solanum melongena* Linn) fruit," *Asian Journal of Research in Medical and Pharmaceutical Sciences*, vol. 5, pp. 1-10, 2018. Available at: <https://doi.org/10.9734/ajrimps/2018/45933>.
- [8] K. Umesh, K. B. Vijay, K. B. Nikunj, P. B. Neha, and A. G. Baljibhai, "Antioxidant and nutritional components of egg plant (*Solanum melongena* L.) fruit grown in Saurashtra region," *International Journal of Current Microbiology and Applied Science*, vol. 4, pp. 806-813, 2015.
- [9] Y. I. Kwon, E. Apostolidis, and K. Shetty, "In vitro studies of eggplant (*Solanum melongena*) phenolics as inhibitors of key enzymes relevant for type 2 diabetes and hypertension," *Bioresource Technology*, vol. 99, pp. 2981-2988, 2007. Available at: <https://doi.org/10.1016/j.biortech.2007.06.035>.
- [10] F. Albouchi, M. Attia, M. Hanana, and L. Hamrouni, "Ethnobotanical notes and phytopharmacological properties on solanum nigrum Linn. (Family: Solanaceae)," *American Journal of Phytomedicine & Clinical Therapy*, vol. 6, pp. 1-5, 2018.
- [11] I. F. Ossamulu, H. O. Akanya, A. A. Jigam, E. Egwim, and H. Adeyemi, "Hypolipidemic properties of four varieties of eggplants (*Solanum melongena* L.)," *International Journal of Pharmaceutical Science Invention*, vol. 3, pp. 47-54, 2014.
- [12] U. O. Mbah and A. C. C. Egbuonu, "Ameliorative potentials of egg plant (*Solanum melongena* Linn) fruit ethanol extract on monosodium glutamate-intoxicated rats' lipid profile, haematology and heart histology," *International Journal of Biochemistry Research & Review*, vol. 18, pp. 1-10, 2017.
- [13] U. O. Mbah, A. C. C. Egbuonu, N. K. Achi, I. D. Nwanne, and O. Jeremiah, "Hepatoprotective potentials of ethanol extract of solanum melongena Linn fruit on monosodium glutamate-intoxicated rats' and liver section histology," *International Blood Research & Reviews*, vol. 9, pp. 1-9, 2019. Available at: <https://doi.org/10.9734/ibrr/2019/45935>.

- [14] H. O. Akanya, I. F. Ossamulu, F. S. Adefolalu, and A. V. Oloniya, "Preliminary investigation of the renal toxicity of monosodium glutamate in rats determined by some serum biochemical markers," *Journal of Advances in Medical and Pharmaceutical Sciences*, vol. 6, pp. 1-8, 2016. Available at: <https://doi.org/10.9734/jamps/2016/19825>.
- [15] C. A. C. Egbuonu, E. P. Madus, and O. L. Nnamdi, "Influence of sub-chronic oral exposure to high monosodium glutamate on some serum markers of the renal functions in male Wistar rats," *African Journal of Biochemistry Research*, vol. 4, pp. 225-228, 2010.
- [16] V. Sharma and R. Deshmukh, "Ajimomoto (MSG): A fifth taste or bio bomb," *European Journal of Pharmaceutical and Medical Research*, vol. 2, pp. 381-400, 2015.
- [17] A. C. C. Egbuonu, "Sub-chronic concomitant ingestion of L-arginine and monosodium glutamate improves feed efficiency, lipid metabolism and antioxidant capacity in male Wistar rats," *Pakistan Journal of Biological Sciences*, vol. 15, pp. 301-305, 2012. Available at: <https://doi.org/10.3923/pjbs.2012.301.305>.
- [18] U. O. Mbah and A. C. C. Egbuonu, "Alcohol-induced teratogenesis: Biochemical basis, management strategies and possible ameliorative roles of L-arginine," *Annals of Agriculture and Environmental Science*, vol. 1, pp. 1-6, 2016.
- [19] A. C. C. Egbuonu, C. I. Opara, O. C. Atasie, and U. O. Mbah, "Vitamins composition and antioxidant properties in normal and monosodium glutamate-compromised rats' serum of Persea Americana (Avocado Pear) seed," *Open Access Journal of Chemistry*, vol. 1, pp. 19-24, 2017.
- [20] A. C. C. Egbuonu and S. O. Oriji, "Pulverized mangiferaindica(mango) seed kernel mitigated monosodium glutamate intoxicated rats' kidney histology and biofunctions," *Journal of Nutritional Health and Food Science*, vol. 2, pp. 1-7, 2017. Available at: <https://doi.org/10.15226/jnhfs.2017.00193>.
- [21] M. Thomas, K. Sujatha, and S. George, "Protective effect of Piper longum Linn. on monosodium glutamate induced oxidative stress in rats," *Indian Journal of Experimental Biology*, vol. 47, pp. 186-192, 2009.
- [22] National Institutes of Health Office of Extramural Research, "Office of laboratory animal welfare. Health Research Extension Act of 1985 (2016, february 13)." Available: <http://grants.nih.gov/grants/olaw/references/phspol.htm#HealthResearchExtensionActof1985>, 1985.
- [23] M. W. Weatherburn, "Phenol hypochlorate reaction for determination of ammonia," *International Journal of Analytical Chemistry*, vol. 39, pp. 971-974, 1967. Available at: <https://doi.org/10.1021/ac60252a045>.
- [24] R. J. Henry, D. C. Cannon, and J. W. Winkelman, *Clinical chemistry principles and techniques*, 2nd ed. Hagerstown, Maryland, USA: Harper and Row, 1974.
- [25] L. T. Skeggs and H. Hochstrasser, "Multiple automatic sequential analysis," *Clinical Chemistry*, vol. 10, pp. 918-936, 1964.
- [26] P. Trinder, "A rapid method for the determination of sodium in serum," *Analyst*, vol. 76, pp. 596-599, 1951. Available at: <https://doi.org/10.1039/an9517600596>.
- [27] R. A. B. Drury, E. A. Wallington, and R. Cameron, *Carleton's histological techniques*, 4th ed. NY, USA: Oxford University Press, 1967.
- [28] SPSS, *Statistical package for the social sciences (SPSS) for windows version 22.0*. New York: SPSS Inc, 2015.
- [29] H. Inuwa, V. Aina, and L. Ja, "Determination of nephrotoxicity and hepatotoxicity of monosodium glutamate (MSG) consumption," *British Journal of Pharmacology and Toxicology*, vol. 2, pp. 148-153, 2011.
- [30] A. Eweka, "Histological studies of the effects of monosodium glutamate on the kidney of adult Wistar rats," *The Internet Journal of Health*, vol. 6, pp. 1-6, 2006. Available at: <https://doi.org/10.5580/7d9>.

*Views and opinions expressed in this article are the views and opinions of the author(s), Journal of Diagnostics shall not be responsible or answerable for any loss, damage or liability etc. caused in relation to/arising out of the use of the content.*